



# Semen quality of the Bernese Mountain Dogs in Sweden

---

*Spermakvalitet hos berner sennen i Sverige*

Angus Lau

Degree project/Independent project • 30 credits  
Swedish University of Agricultural Sciences, SLU  
Faculty of Veterinary Medicine and Animal Science  
Veterinary Medicine Programme  
Uppsala 2021





# Semen quality of the Bernese Mountain Dogs in Sweden

*Spermakvalitet hos berner sennen i Sverige*

Angus Lau

**Supervisor:** Bodil Ström Holst, Swedish University of Agricultural Sciences,  
Department of Clinical Sciences

**Assistant supervisor:** Ida Hallberg, Swedish University of Agricultural Sciences,  
Department of Clinical Sciences

**Examiner:** Eva Axné, Swedish University of Agricultural Sciences,  
Department of Clinical Sciences

**Credits:** 30 HEC  
**Level:** A2E  
**Course title:** Independent project in Veterinary Medicine  
**Course code:** EX0869  
**Programme/education:** Veterinary Medicine Programme  
**Course coordinating dept:** Department of Clinical Sciences

**Place of publication:** Uppsala

**Year of publication:** 2021

**Keywords:** Semen quality, sperm defect, Bernese mountain dog, sperm morphology

**Swedish University of Agricultural Sciences**  
Faculty of Veterinary Medicine and Animal Sciences  
Department of Clinical Sciences

## Publishing and archiving

Approved students' theses at SLU are published electronically. As a student, you have the copyright to your own work and need to approve the electronic publishing. If you check the box for **YES**, the full text (pdf file) and metadata will be visible and searchable online. If you check the box for **NO**, only the metadata and the abstract will be visible and searchable online. Nevertheless, when the document is uploaded it will still be archived as a digital file.

If you are more than one author you all need to agree on a decision. Read about SLU's publishing agreement here: <https://www.slu.se/en/subweb/library/publish-and-analyse/register-and-publish/agreement-for-publishing/>.

YES, I/we hereby give permission to publish the present thesis in accordance with the SLU agreement regarding the transfer of the right to publish a work.

NO, I/we do not give permission to publish the present work. The work will still be archived and its metadata and abstract will be visible and searchable.

## Abstract

This study aimed to have a better understanding of the semen quality of the Bernese mountain dog population in Sweden. Semen and blood samples were collected from 65 male Bernese mountain dogs, both breeding dogs and dogs not intended for breeding. Examination of testicles and prostates were also performed. Semen analysis revealed that sperm motility was negatively associated with age ( $p=0.049$ ). Percentages of detached heads ( $p=0.004$ ) and proximal cytoplasmic droplets ( $p=0.009$ ) were positively associated with age. Percentages of pathological heads ( $p=0.002$ ), proximal cytoplasmic droplets ( $p=0.008$ ), knobbed acrosomes ( $p=0.008$ ) and vacuoles ( $p=0.004$ ) were significantly higher in dogs with abnormal testicle consistency. The percentage of morphologically normal sperm ( $p<0.001$ ) and the number of live morphologically normal sperm ( $p=0.034$ ) were significantly lower in dogs with abnormal testicle consistency ( $p<0.001$ ). For dogs that had been breeding, sperm motility was significantly higher among those with offspring than those without ( $p=0.013$ ).

*Keywords:* semen quality, sperm defect, Bernese mountain dog, sperm morphology

## Sammanfattning

Denna studie syftade till att få en helhetsbild av spermakvaliteten hos berner sennenhundar i Sverige. Spermaprov och blodprov samlades in från 65 berner sennenhundar, både avelshundar och hundar som inte gick i avel. Undersökning av testiklar och prostata utfördes också. Resultatet visade ett negativt samband mellan spermernas rörlighet och ålder ( $p=0,049$ ). Procentandelen lösa huvuden ( $p=0,004$ ) och proximala cytoplasmatiska droppar ( $p=0,009$ ) visade positiva samband med åldern. Procentandelen patologiska huvuden ( $p=0,002$ ), proximala cytoplasmatiska droppar ( $p=0,008$ ), specifik akrosomdefekt ( $p=0,008$ ) och kärnsäckar ( $p=0,004$ ) var signifikant högre hos hundar med onormala testikelkonsistens. Andelen morfologiskt normala spermier ( $p<0,001$ ) och antalet rörliga morfologiskt normala spermier ( $p=0,034$ ) var signifikant lägre hos hundar med onormal testikelkonsistens. Hos avelshundarna var spermernas rörlighet signifikant högre bland de med avkomma än de utan ( $p=0,013$ ).

*Nyckelord:* spermakvalitet, spermiedefekt, berner sennenhund, spermimorfologi

# Table of contents

\_Toc75203519

<b>List of tables .....</b>	<b>9</b>
<b>List of figures.....</b>	<b>10</b>
<b>Abbreviations .....</b>	<b>11</b>
<b>1. Introduction.....</b>	<b>13</b>
<b>2. Literature study .....</b>	<b>14</b>
2.1. Spermatogenesis.....	14
2.2. Semen quality .....	15
2.2.1. Colour .....	15
2.2.2. Motility.....	16
2.2.3. Total number of spermatozoa.....	16
2.2.4. Alkaline phosphatase.....	16
2.3. Sperm morphology and defects .....	17
2.3.1. Classification.....	17
2.3.2. Head defect.....	19
2.3.3. Midpiece defects .....	21
2.3.4. Tail defects.....	22
2.4. Factors affecting sperm quality and spermatogenesis.....	23
2.4.1. Age.....	24
2.4.2. Infection and medication .....	24
2.4.3. Size of the dog and the testes .....	25
2.4.4. Prostate disorder.....	25
2.4.5. Inbreeding .....	26
2.5. Fertility .....	26
2.5.1. Azoospermic dogs .....	27
2.6. Bernese Mountain Dog (BMD) .....	27
<b>3. Method and material.....</b>	<b>29</b>
3.1. Recruitment of participants.....	29
3.2. Background information.....	29
3.3. Physical examination.....	29

3.4.	Sample collection .....	30
3.5.	Analysis .....	30
3.5.1.	Semen evaluation .....	30
3.5.2.	Spermatozoal morphology .....	30
3.5.3.	ALP .....	34
3.6.	Statistical analysis .....	34
<b>4.</b>	<b>Result.....</b>	<b>35</b>
4.1.	Background information.....	35
4.2.	Medical history.....	36
4.3.	Examination of testicle and prostate .....	36
4.4.	Semen quality and sperm defects .....	38
4.4.1.	Descriptive statistic .....	38
4.4.2.	Association between variables .....	41
4.5.	Breeding history.....	43
<b>5.</b>	<b>Discussion.....</b>	<b>45</b>
5.1.	Background information.....	45
5.2.	Semen quality .....	46
5.2.1.	Semen quality .....	46
5.2.2.	Specific defects.....	47
5.3.	Breeding dogs .....	49
5.4.	Conclusion .....	50
	<b>Reference list.....</b>	<b>51</b>
	<b>Acknowledgements.....</b>	<b>58</b>
	<b>Popular science summary.....</b>	<b>59</b>



## List of tables

Table 1. Background information of the participants. ....	35
Table 2. History of medical treatment of the included dogs.....	36
Table 3. Testicle size. ....	37
Table 4. Result of prostate examination .....	38
Table 5. Semen quality and prevalence of sperm defects.....	39
Table 6. Presence of cells in semen samples. ....	41
Table 7. Descriptive statistics of dogs in breeding. ....	43
Table 8. Descriptive statistics of the 13 dogs who had mated within two months of sample collection with confirmed pregnancy. ....	44

## List of figures

Figure 1. Sperms with pathological heads: a) abaxial insertion; b) abnormal contour; c) pear-shaped head; d) narrow at base; e) variable sizes and f) undeveloped sperm cell. ....	31
Figure 2. Sperms with a) knobbed acrosome and b) nuclear vacuoles (craters). ...	32
Figure 3. Sperms with cytoplasmic droplets: a) proximal droplet and b) distal droplet. ....	32
Figure 4. Midpiece defect - defective midpiece (Formol-saline solution). ....	33
Figure 5. Sperms with tail defects: a) single bent tail; b) coiled tail and c) double bent tail. ....	33
Figure 6. Presence of other cells in the semen sample: a) epithelial cell and b) neutrophil.....	34
Figure 7. Histogram of age, Body Condition Score (BCS) and weight of the included dogs. ....	35
Figure 8. Boxplot of age and testicle consistency of the included dogs. ....	37
Figure 9. Histogram of scrotal width and testicle total volume of the included dogs. ....	37
Figure 10. Histogram of ejaculate volume, motility, total sperm number, percentage of morphologically normal sperms (MNS), number of morphologically normal sperms (MNS), number of live morphologically normal sperms (MNS) and alkaline phosphatase (ALP).....	40
Figure 11. Histogram of sperm defects. ....	40
Figure 12. Scatterplot of Motility (%) vs Age (month) ( $p=0.0049$ ). ....	41
Figure 13. Boxplot of pathological heads ( $p=0.002$ ), proximal droplets ( $p=0.008$ ), knobbed acrosomes ( $p=0.008$ ) and vacuoles ( $p=0.004$ ) in dogs with normal and abnormal testicle consistency. ....	42
Figure 14. Scatterplot of proximal droplets ( $p=0.009$ ) and detached head ( $p=0.004$ ) vs Age (months). ....	42

## Abbreviations

AI	Artificial insemination
ALP	Alkaline phosphatase
BCS	Body condition score
BPH	Benign prostatic hypertrophy
BMD	Bernese mountain dog
BSE	Breeding soundness evaluation
DNA	Deoxyribonucleic acid
ICSI	Intracytoplasmic sperm injection
IVF	<i>In vitro</i> fertilization
KA	Knobbed acrosome
MNS	Morphologically normal spermatozoa
NSAID	Non-steroidal anti-inflammatory drugs
SLU	Swedish University of Agricultural Sciences
TEM	Transmission electron microscopy
UDS	University Animal Hospital at SLU



# 1. Introduction

This project was conducted in cooperation with the Svenska Sennenhundklubben (The Swedish mountain dog breed club). The breed club had been noticing a trend of impaired fertility within the breed with low whelping rates, small litter sizes and high number of still-born puppies. The Swedish University of Agricultural Sciences (SLU) was contacted and it was decided to conduct a project regarding this problem of impaired fertility. The project was divided into two subprojects, one studying female factors, and the other male factors. The male side was led by my supervisor Bodil Ström Holst and assistant supervisor Ida Hallberg.

The aim of this project was to gain an overview of the semen quality in the Swedish population of the Bernese mountain dogs (BMD) and to identify associations between semen quality and the traits of the participating dogs and, if possible, contribute to the understanding of the reproductive capacity of this particular breed.

## 2. Literature study

### 2.1. Spermatogenesis

Spermatogenesis occurs in the testes while the maturation, transport and storage take place in the epididymis (Chłopik & Wysokińska 2020). Duration of spermatogenesis in dog is 62 days (Johnston *et al.* 2001).

Spermatogenesis consists of three phases: spermatocytogenesis, spermiogenesis and spermiation and it takes place in the germinal epithelium of the seminiferous tubules (Johnston *et al.* 2001; Chłopik & Wysokińska 2020). The seminiferous tubules are lined by the germ cells and the Sertoli cells which support, provide nutrients and regulate the maturation of the developing germ cells (Linde-Forsberg 2001; Sjaastad *et al.* 2010).

During spermatocytogenesis, the first stage of spermatogenesis, the spermatogonia located at the basal membrane of the seminiferous tubules undergo mitosis and primary spermatocytes are produced. The primary spermatocytes then undergo the first meiotic division into secondary spermatocytes which in turn go through second meiotic division into spermatids (Sjaastad *et al.* 2010). The second stage of spermatogenesis, spermiogenesis, involves cell differentiation of spermatids into their mature forms (Chłopik & Wysokińska 2020). During the spermiation, the last stage of the spermatogenesis, the mature spermatids are released into the lumen of the seminiferous tubules and become spermatozoa (Chłopik & Wysokińska 2020).

During the epididymal transit the spermatozoa mature and become motile (Angrimani *et al.* 2014), the cytoplasmic droplets migrate distally and the acrosome is reshaped (Linde-Forsberg 2001; Varesi *et al.* 2013). Higher percentages of intact plasma membranes and intact acrosome membranes were found in cauda epididymis than in corpus and caput (Angrimani *et al.* 2014). The duration of the epididymal transit is around 15 days (Linde-Forsberg 2001). The spermatozoa are stored in the cauda epididymis until ejaculation (Chłopik & Wysokińska 2020).

## 2.2. Semen quality

The semen quality of the dog is related to the function of the testes, epididymides and prostate (Kolster 2018). Dogs ejaculate in three fractions. The first fraction originates from the prostate and is usually clear or slightly cloudy, and it is discharged during courting and mounting of the female dog. The second fraction is the sperm-rich fraction and usually appears opaque or milky white, depending on sperm concentration. The volume ranges from 0.5 to 3 ml and it is emitted after intromission and before the copulatory tie. The third fraction, the prostatic fraction, is normally clear. It is the fraction with the largest volume (up to 30-40 ml for larger breeds) and is released during the copulatory tie (Linde-Forsberg 2001; Freshman 2002; Kolster 2018). The volume of the ejaculate mainly depends on the volume of the third fraction, and the second, sperm-rich fraction is the most important fraction for semen quality evaluation (Kolster 2018).

Common reasons for performing a semen analysis are breeding soundness evaluation, obtaining semen for artificial insemination (AI) and also preservation for chilling and freezing (Johnston 1991; Root Kustritz 2007). Before semen evaluation, the signalment and history of the patient are recorded, and a physical examination should be performed. Semen samples can be collected by manual ejaculation which is the most common method used in dogs (Johnston *et al.* 2001). The presence of a friendly, proestrous or oestrous teaser bitch that is close to the size of the male dog is recommended. After a semen sample is collected it is evaluated both macroscopically and microscopically (Feldman 2004). Macroscopic evaluation includes volume, colour and pH of the semen while microscopic evaluation consists of motility, concentration, morphology of the spermatozoa and cytology (Feldman 2004). Bacterial culture can also be performed to identify infections of the reproductive tract (Feldman 2004). Multiple collections are often recommended for a better assessment of semen quality (Freshman 2001).

Knowledge about how seminal quality can predict or correlate with fertility is limited (Saacke *et al.* 2000; Root Kustritz 2007) and only approximately 50-60% of variation in fertility among males can be accounted for by examining seminal traits (Saacke 2008).

### 2.2.1. Colour

According to Johnston *et al.* (2001) normal canine semen should be cloudy white to opalescent. Red colour indicates the presence of fresh blood, and brown colour indicates old blood, common causes are prostatic disease and trauma to the penis (Johnston *et al.* 2001; Root Kustritz 2007). Yellow colour suggests the presence of

urine while green indicates a purulent exudate (Johnston *et al.* 2001). Colourless or clear semen can indicate azoospermia (Johnston 1991)

### 2.2.2. Motility

Normal motility is described as rapid, progressive, forward motion (Feldman 2004). Studies have stated that at least 70% of spermatozoa should show normal progressive motility when semen is evaluated immediately after semen collection (Johnston 1991; Linde-Forsberg 1991; Freshman 2002; Feldman 2004).

Mickelsen *et al.* (1993) studied the pregnancy rate after artificially inseminating 31 bitches (10 different breeds of medium to large size) with fresh undiluted semen (breeds of the male unstated, they weighed between 15-70 kg). They found that the total number of progressively motile or morphologically normal spermatozoa (MNS) had a significant impact on the pregnancy rate, whereas the percentage of the progressively motile or morphologically normal spermatozoa did not influence the pregnancy rate. This result is in accordance with Saacke *et al.*'s (2000) definition of compensable semen traits (further described in section 2.3.1 Classification below). Immotile spermatozoa are precluded from accessing the site of fertilization as they fail to ascend the female reproductive tract (Overstreet *et al.* 1978), however, this can be compensated for by increasing the number of functionally competent spermatozoa and fertility can thus be improved (Saacke *et al.* 1998). Mickelsen *et al.* (1993) also found that the litter size was not affected by motility or morphology of the spermatozoa.

### 2.2.3. Total number of spermatozoa

According to Johnston (1991) and Root Kustritz (2007) the normal total number of spermatozoa for dog per ejaculate is between 300 million and 2 billion. In a study in which semen samples were collected from dogs with different size, the mean total sperm number for dogs larger than 40kg was  $693 \pm 83 \times 10^6$  (Tesi *et al.* 2018).

As mentioned in section 2.2.2. the total number of MNS has a significant influence on pregnancy rate. The result of the same study mentioned above conducted by Mickelsen *et al.* (1993) showed that AI (semen deposited into the cranial area of the vagina) with ejaculates containing more than 250 million MNS yielded a pregnancy rate of 81.5% while no pregnancy was achieved by AI with ejaculate with less than 220 million total number of MSN.

### 2.2.4. Alkaline phosphatase

Seminal fluid of incomplete ejaculation from normal intact male dogs usually contains less than 5000 U/L alkaline phosphatase (ALP) (Johnston *et al.* 2001,



p.375). ALP is an epididymal marker and its activity was found to be much higher in the epididymis than in the testis and prostate, especially in the cauda epididymis (Frenette *et al.* 1986). When an azoospermic semen sample is obtained, analysis of the ALP concentration can verify if the ejaculation was complete or not. Low ALP can also indicate bilateral epididymal obstruction (Kolster 2018).

## 2.3. Sperm morphology and defects

A normal spermatozoon consists of an acrosome, head, neck, midpiece and tail (principal piece and end piece), the midpiece is normally about 1.5 times the length of the head (Feldman 2004). The heads of the spermatozoa contain the nuclei and the acrosome cap is filled with hydrolytic enzymes that are required to penetrate the oocyte during fertilization (Sjaastad *et al.* 2010).

The percentage of spermatozoa with normal morphology in normal canine semen has been suggested to be at least 70-80% (Johnston 1991; Feldman 2004). According to Oettlé's study (1993) on sperm morphology and fertility, fertility is affected when the MNS falls below 60% in dogs. The morphology of the spermatozoa might differ with different staining or preparation techniques (Root Kustritz *et al.* 1998).

### 2.3.1. Classification

There are different classification systems for sperm abnormalities. Sperm defects can be categorized by the localisation of the defect. In this section three different classification systems are described. Definitions and classifications of sperm defects have changed due to the progress of research and technology.

#### *Primary or secondary defect*

Abnormalities can be categorized as primary or secondary depending on where the defects have originated (Seager 1986; Plummer *et al.* 1987; Johnston *et al.* 2001; Chenoweth 2005; Bhanmeechao *et al.* 2018). Primary defects occur during spermatogenesis. Secondary defects occur after spermiation, during sperm maturation in the epididymis or during collection and preparation of the sample (Seager 1986; Johnston *et al.* 2001; Freshman 2002; Chenoweth 2005). Primary defects are commonly regarded as more serious than secondary defects.

Primary defects include the following, grouped by the localisation of the defect (Barth & Oko 1989 see Kolster 2018; Johnston 1991; Freshman 2001, 2002; Feldman 2004; Chenoweth 2005)::

- Head: all abnormal head shapes, pear-shaped (pyriform), narrow head (tapered head), microcephalic, macrocephalic, double head, deformed head, knobbed acrosome and nuclear vacuoles (diadem defect).
- Midpiece: double midpiece, proximal cytoplasmic droplets, frayed thin midpiece, thickened midpiece, ruptured midpiece.
- Tail: Dag defect, double tail
- Other defect: teratoid form

Secondary defects include (Barth & Oko 1989 see Kolster 2018; Johnston 1991; Feldman 2004; Freshman 2001, 2002):

- Head: detached normal heads, detached acrosome
- Midpiece: distal cytoplasmic droplets, bowed midpiece
- Tail: bent principal piece, coiled principal piece

The classification of abaxial attachment of tail and multiple tail is inconsistent in the literature (Feldman 2004; Kolster 2018).

Neither primary nor secondary defects should exceed 20%. An increased number of secondary defects can be indicative of infection in the reproductive organs or other non-specific conditions (e.g. fever, trauma or glucocorticoid treatment) (Johnston 1991; Feldman 2004).

#### *Major or minor defects*

Furthermore, sperm defects can also be sorted by their impact on male fertility and be categorized into either major defects or minor defects. Major defects are related to infertility while minor defects are generally considered to have less influence on male fertility (Blom 1973). However, Root Kustritz (2007:331) expressed her concern about this way of classification as it “implies scientific knowledge of effect of morphologic defects on fertility in dogs”.

Examples of major defects include the following (Blom 1973)

- Head: underdeveloped, double forms, knobbed acrosome, decapitated sperm defect, diadem defect, pear-shaped defect, narrow at base, abnormal contour, microcephaly, detached pathological head,
- Midpiece: corkscrew defect, tail stump, proximal droplets, pseudodroplets, ruptured midpiece, kinked midpiece
- Tail: ‘dag’ defect, strongly coiled or folded tail, double tail
- Broken neck and teratoid form.

While minor defects include the following (Blom 1973)

- Head: narrow heads, small normal heads, giant and short broad heads, detached normal heads, detached acrosome membranes

- Midpiece: abaxial implantation, distal droplets
- Tail: simple bent tail, terminally coiled tail
- Other abnormal cells (epithelial cells, erythrocytes, medusa formation, boat cells, round cells and pus cells).

A study showed that deoxyribonucleic acid (DNA) fragmentation was associated with major sperm defects but not with minor sperm defects in bulls (Enciso *et al.* 2011). It was also shown that a few of the major sperm abnormalities, namely double forms, narrow at base, small abnormal heads and tail stump, were exclusively associated with DNA fragmentation, while minor defects could be found in both DNA fragmented sperm and sperm with intact DNA (Enciso *et al.* 2011). They speculated the causal relationship between DNA fragmentation and major defects, either that the defected sperm produced fragmented DNA to signal for apoptosis or that the morphological defects were caused by the damaged DNA (Enciso *et al.* 2011).

#### *Compensable and uncompensable*

Sperm defects that result in impaired pregnancy rates can be regarded as compensable or uncompensable (Saacke *et al.* 2000). If the impaired fertility is due to hindered access to the egg or insufficient interaction with the ovum to induce fertilization and the block to polyspermy then the defect is regarded as compensable, and fertilization rate can be improved by increasing the sperm numbers (Saacke 2008). If a defect does not impair the access of a spermatozoon to the ovum but it prevents a spermatozoon from initiating fertilization and/or embryogenesis and does not sustain either event once initiated, such defect is regarded as uncompensable, as the fertility is independent of sperm dosage (Saacke *et al.* 1998; Saacke 2008). Uncompensable traits have been associated with defects in spermatozoal chromatin (Saacke 2008).

Defects that interfere with motility of the spermatozoa for example tail defects and cytoplasmic droplets are examples of compensable traits and can be compensated by increasing the number of normal motile spermatozoa (Saacke *et al.* 1998).

#### **2.3.2. Head defect**

In a study the morphology of the accessory sperm (according to Munkittrick *et al.* (1992) accessory sperms are spermatozoa captured in the zona pellucida following penetration of the fertilizing sperm) was examined after inseminating cows (Saacke *et al.* 1998). It was found that spermatozoa with severely misshaped heads were precluded from accessing the ovum and/or participating in fertilization while sperm with subtle deviations in head shape and sperm with nuclear vacuoles (normal head

shape) could access the ovum. Abnormal head morphology can thus have both a compensable and an uncompensable component (Saacke *et al.* 1998).

#### *Detached head*

The head of the spermatozoa can easily detach during the passage through the epididymis (Kawakami *et al.* 2005) and under manipulation after semen collection (Chłopik & Wysokińska 2020). In this case it is counted as a secondary defect which occurs after the testes. However, the decapitation can also happen during spermiogenesis (Chenoweth 2005) and in this case the defect is counted as primary. According to the categorisation above this defect would be classified as major if the head has abnormal morphology and minor if the head morphology is normal.

#### *Knobbed acrosome*

The knobbed acrosome (KA) defect has been reported in bulls (Barth 1986), boars (Toyama & Itoh 1993) and dogs (Santos *et al.* 2006). Sperm with this defect show an eccentric thickening of the anterior part of the head with an “abnormal swollen, 'cystic' apical body containing inclusion” (Blom 1973:384). It can also appear as flattened or indented apex of the sperm head (Barth 1986). In the bull it was reported to have a high incidence in the Charolais breed (Barth 1986). From the case report of four closely related dogs (Santos *et al.* 2006:1627) with KA defects, the defect appeared mainly in two forms, a folded (lipped) acrosome which contributes to a “square appearance of the apical end of the sperm head” while the other form had a nipple-like branch at the apical side of the sperm head. When examined with Transmission electron microscopy, both forms of KA defects contained a vesicular structure which was often filled with membranous material (Santos *et al.* 2006:1627). As all four dogs were closely related a genetic component of KA was suggested in this case.

In one study (Thundathil *et al.* 2000) the effect of the KA defect in bovine spermatozoa on fertilization was studied by comparing three bulls with such sperm defects with a control bull. The mean number of spermatozoa binding to zona pellucidae and the percentage of penetration of zona pellucidae was lower for the bulls with KA compared to the control bull (Thundathil *et al.* 2000). Most importantly the fertilization rate was lower for the bulls with KA. The authors suggested that KA is an uncompensable defect (Thundathil *et al.* 2000). Another study of the sperm after uterine insemination in cows showed that the proportion of sperm with KA was significantly lower in the anterior part of the reproductive tract which indicated that sperm with this defect were retained by the reproductive tract (Mitchell *et al.* 1985). The mechanism of this differential retention is not known.

A higher proportion of spermatozoa with intact acrosomes were found in the cauda epididymis than from the caput and corpus (Varesi *et al.* 2013) which implied an association between acrosome abnormality and sperm immaturity.

#### *Vacuoles*

Sperm head vacuoles were described as unstained vacuolar areas in the headpiece (World Health Organization 1999) and appeared as “pocket-like” nuclear concavities under high magnification of light microscopy (Fekonja *et al.* 2014) in human sperm. When the vacuoles are distributed in random fashion it is called craters while it is called diadem defect when the vacuoles are distributed uniformly at the nuclear ring (Saacke *et al.* 1998). In Fekonja *et al.*'s study (2014) it was shown that vacuoles were found in both normospermic and teratozoospermic semen samples in men but percentages were significantly higher in teratozoospermic samples. They also discovered that sperm head vacuoles were related to a decreased fertilization rate in classical in vitro fertilization (IVF) but not using intracytoplasmic sperm injection (ICSI). Saacke *et al.*'s (1998) study of morphology of accessory sperm in inseminated cows demonstrated that the proportion of sperm with normal head shape, but with nuclear vacuoles did not differ significantly between accessory sperms and the total number of sperm inseminated. This implies that sperm with nuclear vacuoles could be capable of accessing the ovum and even compete for fertilization if the head shape is normal. The impact of nuclear vacuoles on fertilization rate in dogs will require further research. The diadem defect is an indicator of disturbed spermiogenesis (Blom 1973). When examined by electron microscope, the defect was shown to be consisting of invaginations of the nuclear envelope (Blom 1973). This defect has been found in dogs and it did not seem to be hereditary (Dahlbom *et al.* 1997).

### 2.3.3. Midpiece defects

#### *Cytoplasmic droplets*

Cytoplasmic droplets are categorized as a midpiece defect in several studies (Freshman 2002; Kolster 2018; Tesi *et al.* 2018) or grouped as its own category in other studies (Oettlé 1993; Brito *et al.* 2018). Cytoplasmic droplets originate from the germ cell cytoplasm. The migration of the cytoplasmic droplet from a proximal to a distal position along the midpiece during epididymal passage was first reported by Merton (1940) in mice and was later confirmed in other species as cats, dogs, rams and monkeys (Amann *et al.* 1982; Axnér *et al.* 1999; Varesi *et al.* 2013; Xu *et al.* 2013; Angrimani *et al.* 2014). In cats the migration of the cytoplasmic droplet has been shown to take place in the last region of the corpus epididymis (Axnér *et al.* 1999). In dogs the migration was suggested to happen between the caput and corpus epididymis (Varesi *et al.* 2013). The retention of proximal droplets can

suggest abnormal epididymal maturation (Cooper 2005; Chłopik & Wysokińska 2020). Another study in bulls has, however, suggested that the migration of proximal droplets is determined by factors in the testes (Rao *et al.* 1980). Other studies have also shown evidence that cytoplasmic droplets are shed during ejaculation in boars (Lasley & Bogart 1944), cats (Axnér *et al.* 1998) and in mice (Xu *et al.* 2013).

Two case reports indicate an association between infertility and proximal cytoplasmic droplets in dogs (Plummer *et al.* 1987; Peña *et al.* 2007). In Peña *et al.*'s (2007) case study of a 4 year old male dog which was unable to impregnate three bitches after mating, the dog had normal sperm count and 80% of progressively motile spermatozoa but a high percentage of proximal cytoplasmic droplets. They showed that the spermatozoa with proximal cytoplasmic droplets appeared to have reduced ability to capacitate *in vitro* which implied impaired ability to bind to zona pellucida (Peña *et al.* 2007).

A study of fertility of stored boar semen found that the percentage of proximal droplets negatively correlated with the pregnancy rates and litter sizes (Waberski *et al.* 1994). Another study with the focus on the impact of proximal droplets on a bull semen sample's fertilizing potential using IVF found that a high proportion of proximal droplets significantly decreased fertility (Amann *et al.* 2000). Binding capacity of spermatozoa to the oviductal epithelium in pig *in vitro* was shown to have a negative association with percentage of spermatozoa with cytoplasmic droplets and the percentage of morphologically abnormal spermatozoa (Petrunkina *et al.* 2001). Further studies are needed for a better understanding of how these defects can affect fertility *in vivo* in dogs specifically, but the above-mentioned studies suggest a negative correlation between the proximal droplets and fertility.

#### 2.3.4. Tail defects

It is reasonable to suspect that tail defects would depress the progressive motility of the affected spermatozoa as sperm motility is driven by a motile cytoskeletal unit (axonemes) in the tail (Inaba & Mizuno 2016). According to Mitchell *et al.* (1985) spermatozoa with tail defects are evidently hindered at barriers in the female reproductive tracts. Therefore, tail defects that impair motility can be regarded as compensable defects (Saacke *et al.* 1998).

##### *Dag defect*

“Dag-like” or simply “Dag” defect is a defect that was first reported in a Jersey bull named “Dag” (Blom 1966). This defect is classified as tail defect in some literature (Rota *et al.* 2008; Villaverde *et al.* 2013) and midpiece defect in other (Chenoweth 2005; Root Kustritz 2007). According to Chenoweth (2005:464) the “Dag” defect is expressed as “strong folding, coiling and fracture of the distal part of the sperm

midpiece”, another similar definition was provided by Villaverde *et al.* (2013:317) as “sperm tail defect characterized by multiple fractures of the axonemal fibres, and mitochondrial sheath disruption”.

In a case study of an English bulldog with severe teratozoospermia which mainly consisted of “Dag-like” tail coiling (Rota *et al.* 2008), the ultrastructure of the sperm was studied and showed a thin membrane encapsulating the coiled tail and other membranous structures, and swollen and odd scattering of mitochondria (Rota *et al.* 2008). Similar ultrastructural characteristics were found in sperm with the Dag defect from a teratozoospermic cat (Villaverde *et al.* 2013).

#### *Coiled tail*

Aetiology of the of coiled and bent tail is unknown (Luño *et al.* 2020). Chenoweth (2005:465) claimed that simple coiled tails is one of the most common sperm defects and can be genetic, but he also expressed that “increased prevalence of such defects in the ejaculate is associated with one or more of a variety of non-genetic origin aetiologies” Coiled tail, if they are coiled close to the headpiece, can have similar appearance under phase microscope as the Dag defect mentioned above.

#### *Simple bent*

Spermatozoa with simple bent tail have a 180-degree bend on the principle piece of the tail and it is considered to be secondary and minor defect (Kolster 2018).

#### *Double bent*

There is a lack of research conducted about this tail defect.

## 2.4. Factors affecting sperm quality and spermatogenesis

In this section some of the factors that have been linked to sperm quality are discussed.

As the total time for spermatogenesis in dog is approximately 62 days (Johnston *et al.* 2001), abnormal morphology of spermatozoa can be observed long after any insult to the genital tract of a dog.

### 2.4.1. Age

Davies (1996) suggested that defining life stages (young, adult or old) based on age is not optimal as there are considerable differences among different breeds regarding rates of aging and lifestyle, although it is widely acknowledged that small breeds have a longer life expectancy. In another word an 8-year-old dog of a larger breed is considered older than a smaller dog of the same age. The age when dogs reach puberty also varies between breeds and sizes, smaller breeds reach sexual maturity earlier than larger breeds (Johnston *et al.* 2001). In Brito *et al.*'s study (2018) small dogs ( $\leq 15$  kg) were regarded as senile if older than 8 years, while the cut-off point for medium (15–30 kg) and large dogs ( $\geq 30$  kg) was 6 years.

Some previous studies have not shown any effect of age on sperm motility (Hesser *et al.* 2017; Tesi *et al.* 2018) while others have demonstrated a negative association between age and motility (Bhanmeechao *et al.* 2018; Brito *et al.* 2018). There is more consistency regarding the influence of age on sperm morphology, with several studies showing a higher proportion of sperm defects in older dogs than in younger ones (Rijsselaere *et al.* 2007; Hesser *et al.* 2017; Bhanmeechao *et al.* 2018; Brito *et al.* 2018; Tesi *et al.* 2018). Midpiece defects (Tesi *et al.* 2018) and proximal droplets (Brito *et al.* 2018; Tesi *et al.* 2018) were more frequently found in older dogs. The percentage of primary, secondary, major and minor defects was increased in senile dog ( $>9$  years old) (Bhanmeechao *et al.* 2018), suggesting that age affects sperm morphology both in the testes and epididymis. Higher percentages of sperm plasmatic membrane lesions were also found in aging dogs (Brito *et al.* 2018). In contrast to the study conducted by Hesser *et al.* (2017), Bhanmeechao *et al.* (2018) did not find any significant difference in sperm DNA fragmentation between age groups. Volume and total sperm number did not differ between age groups (Tesi *et al.* 2018). Another study stated that spermatogenesis itself does not decline with age in dogs but the risk of testicular tumour increased with ageing which in turn affects spermatogenesis considerably (Peters *et al.* 2000).

### 2.4.2. Infection and medication

Bacteria from the distal part of the urethra and prepuce, even when being part of the normal flora, can ascend and infect the reproductive tract (Johnston 1991). Examples of such bacteria are *Staphylococcus* spp., *Streptococcus* spp., *Escherichia coli*, *Proteus mirabilis*, *Klebsiella pneumonia*, *Hemophilus* sp., *Corynebacterium* spp., and *Moraxella* spp. (Johnston 1991). As mentioned previously an increase number of secondary defects can be the result of infection of the male reproductive organs (Johnston *et al.* 2001).



Medications that can affect spermatozoal production and reproductive function include prednisone, betamethasone, methyltestosterone, testosterone esters, estrogens, progestogens, amphotericin B, cimetidine, clomipramine, and ketoconazole, tamoxifen citrate, gossypol, GnRH agonist and antagonist. Semen evaluation should be performed three months after cessation of the drugs if a dog is treated with above (Freshman 2001; Feldman 2004). If a dog is treated with a subcutaneous implant of GnRH agonist one should wait for at least three months after the expected effect of the implant has ceased before performing a semen collection.

### 2.4.3. Size of the dog and the testes

The normal total number of spermatozoa per ejaculate in a dog is 300 million to two billion (Johnston 1991; Root Kustritz 2007). Larger dogs produce more spermatozoa than smaller dogs (Tesi *et al.* 2018). Dog weight showed a positive correlation with total sperm output (Rijsselaere *et al.* 2007), due to a higher amount of testicular tissue (Johnston *et al.* 2001). Previous studies (Olar *et al.* 1983; Woodall & Johnstone 1988) showed that scrotal width was correlated with testicular weight. Additionally, total scrotal width also showed correlation with daily spermatozoal production and daily spermatozoal output (Olar *et al.* 1983). Therefore, it is practical to estimate the amount of testicular tissue by measuring the total scrotal width to have an approximate assessment of the number of spermatozoa that could possibly be produced and ejaculated. However, the body weight needs to be taken into consideration when one uses this measurement to predict fertility, and normal testis sizes in dogs, as the weight of the testis is highly correlated to the bodyweight (Woodall & Johnstone 1988). Having a normal scrotal width does not guarantee a normal production of spermatozoa (Woodall & Johnstone 1988). The size of the dog has no impact on the proportion of morphologically normal sperm (Tesi *et al.* 2018).

Body condition score (BCS) can be judged using a nine point scales (Laflamme 1997) that is widely used in clinical practice. To my knowledge, no associations between BCS and semen quality has been described in dogs. In humans, both overweight and underweight were significantly associated with reduced total sperm number and total motile sperm count (Ma *et al.* 2019). Obesity also showed significant association with lower semen volume (Ramaraju *et al.* 2018; Ma *et al.* 2019) and higher percentage of head defects (thin heads and pyriform heads) (Ramaraju *et al.* 2018).

### 2.4.4. Prostate disorder

In a study by Flores *et al.* (2017) the reproductive potential between five healthy male dogs and five dogs with benign prostatic hyperplasia (BPH) was compared. Dogs in the control group had sperm with a higher percentage of DNA integrity and

lower percentage of minor sperm defects than dogs in the BPH group. Total motility did not differ between the groups in contrast to another study showing lower total motility in the BPH group (Aquino-Cortez *et al.* 2017). As BPH is common among older dogs it may be wise to perform a prostate examination before mating older dogs to detect individuals who might have lowered potential to impregnate a female.

#### 2.4.5. Inbreeding

The degree of inbreeding can affect fertility and the quality of the ejaculate of male dogs (Wildt *et al.* 1982). Outbred dogs showed a significantly higher mean conception rate and total number of puppies whelped and born alive than inbred dogs. The average total number of sperm per ejaculate was also higher in outbred male dogs (Wildt *et al.* 1982).

According to the general recommendation of the Swedish Kennel Club the degree of inbreeding should be under 2.5% (Svenska Kennelklubben 2014).

### 2.5. Fertility

According to Root Kustritz (2007:329) the knowledge of correlation between findings from semen evaluation and fertility in dogs are limited. The way dogs are kept and bred and their reproductive pattern make them unfit for systematic studies (Linde-Forsberg 1991). Fertility is not an all-or-none trait and semen with poor quality can still lead to pregnancy (Linde-Forsberg 1991).

In order to estimate the reproductive capacity of an animal a breeding soundness evaluation is usually conducted which includes a physical examination, semen collection and evaluation, palpation and measurement of the testes and rectal palpation the prostates (Johnston *et al.* 2001). Tests for *Brucella canis* can also be performed if suspected (Johnston *et al.* 2001)

Both testes should be present in the scrotum. If one or both testes has/have not descended in to the scrotum by the age of six months, the dog suffers from cryptorchidism (Johnston *et al.* 2001). Cryptorchidism is inheritable, the incidence is higher in small breeds and it is associated with higher risk of testicular neoplasia (Johnston *et al.* 2001; Gubbels *et al.* 2009; Khan *et al.* 2018), and therefore dogs with this condition should not be bred even though unilaterally cryptorchid dogs can still produce sperm.

In Tesi *et al.*'s study (2018) they compared the characteristics of semen resulting in pregnancies after AI with samples not resulting in pregnancy, and found that the

total sperm number ( $627.6 \pm 50.4 \times 10^6$  compared to  $389.4 \pm 73.1 \times 10^6$ ), motility ( $83.9 \pm 1.6\%$  to  $66.5 \pm 6.6\%$ ), and proportion of morphologically normal spermatozoa ( $64.9 \pm 3.7\%$  to  $42.0 \pm 8.4\%$ ) was higher in semen samples resulting in pregnancies. Age did not differ significantly between successful and unsuccessful AI (Tesi *et al.* 2018). Hesser *et al.* (2017) studied the association between pregnancy rate and litter sizes and different semen quality parameters in a Labrador breeding facility. They found no difference in age concerning the conception rate, litter size nor other parameters (for example membrane lipid peroxidation and mitochondrial DNA number).

### 2.5.1. Azoospermic dogs

Azoospermia is an ejaculate without the presence of spermatozoa (Feldman 2004; Memon 2007). Azoospermia can be transient or permanent and can originate from retrograde ejaculation, incomplete ejaculation, pretesticular causes, testicular causes or post-testicular causes (Johnston *et al.* 2001; Feldman 2004). During semen collection a male dog can be too anxious or lack sufficient sexual stimulation to ejaculate the sperm rich fraction but only the pre-sperm prostatic fraction, in this case the dog is not truly azoospermic (Memon 2007). Tesi *et al.* (2018) stated that a decrease in the volume and consistency of the testes were noted in azoospermic dogs which implied that palpation can be useful when suspecting such a condition. The ALP concentration in an azoospermic semen sample can be analysed to determine if the ejaculation was complete or not, if the ALP is  $<5000$  U/L then the ejaculation is regarded as incomplete (Memon 2007).

## 2.6. Bernese Mountain Dog (BMD)

According to the breed specific data (collected year 2011-2016) provided by Agria Djurförsäkring (2018), an animal insurance company in Sweden, the BMD (insured by the company) had a higher total morbidity per year at risk (2121 per 10000 years at risk) compared to other breeds (1448 per 10000 years at risk). They had higher morbidity among orthopaedic complaints, neoplasia and gastrointestinal complaints than other breeds (Agria Djurförsäkring 2018).

Previous studies have shown that BMDs have a lower life expectancy than other breeds of similar sizes (Klopfenstein *et al.* 2016). Median life expectancy was 8.4 years, 7.7 years for male dogs, and the most common cause of death was neoplasia (58.3%) in a study of 389 BMDs Klopfenstein *et al.* (2016). Another study of mortality of purebred and mixed-bred dogs in Denmark also showed that BMDs

had shorter median age (7.0 years) than the median age at death for all dogs in the study (10.0 years) (Proschowsky *et al.* 2003).

A breed-specific breeding strategy document was issued by the Swedish mountain dog breed club (Svenska Sennenhundklubbens avelsråd 2018). In this document it is stated that the average litter size was 5.8 (stillborn included) during the period 2011-2015 which was lower than other comparable breeds. The degree of inbreeding for the Swedish population was 0.6-1.2 % during the year 2008-2016.

To the author's knowledge there has not been any previous study focusing on the semen quality and spermatozoal morphology of the BMD breed.

## 3. Method and material

### 3.1. Recruitment of participants

Recruitment of participants was carried out through communication with The Swedish mountain dog breed club and through establishing a Facebook group for the project. A webpage about this project was also set up on the homepage of SLU.

Before the sample collection the dog owners were provided with information of this project in written form, and a consent form was signed.

### 3.2. Background information

Background information of the male dogs was collected including age, weight, microchip number, breeding history (number of previous mating, number of litters and offspring produced), medical history (hormonal treatment, prophylactic treatment against ectoparasites and other treatment administrated) and problems with elimination if any.

### 3.3. Physical examination

The body condition score (9 points scale) was examined (Laflamme 1997). The size (total scrotal width, diameter of each testis, height, and thickness) and consistency of the testes were evaluated. Those with at least one testicle with abnormal consistency were categorized into the “abnormal” group while those with normal consistency for both testicles were categorized into the “normal” group. Total testicle volume was the sum of the volume of each testicle, the volume of each testicle was calculated by the formula (diameter  $\times$  height  $\times$  thickness  $\times \pi \div 6$ ). Rectal palpation of the prostates was also performed (signs of pain under palpation, consistency, symmetry, and size were examined).

## 3.4. Sample collection

Sample collection took place at clinics that participated in the project and were close to the owners, namely the university animal hospital (UDS) and 14 other clinics, and the semen collections were performed by different veterinarians. Samples collected at other clinics were sent to the spermatology laboratory by post.

Semen samples were collected by a veterinarian through manual stimulation of the penis in the presence of a teaser bitch in oestrus (if possible).

Blood sample (EDTA tube and serum tube) were collected after the semen sample was collected and used for other projects My study focuses on semen quality.

## 3.5. Analysis

### 3.5.1. Semen evaluation

The gross appearance of the semen was examined, the colour, volume, and any abnormality of the ejaculate was recorded.

#### *Motility*

The motility (in percentage) of the sperm was assessed subjectively under a phase-contrast microscope immediately after sample collection. A drop of semen was laid on a prewarmed microscope slide and a warm cover glass slip was put on top of the drop. The motility of the sperm was then evaluated under 100 x and 200 x magnification.

#### *Sperm concentration and total sperm number*

The sperm concentration of each semen sample was counted with a haemocytometer (Bürker chamber) and microscope. The analysis was performed at the Spermatology Laboratory, Department of Clinical Sciences, in SLU which is an accredited laboratory.

The total sperm number was calculated by multiplying the sperm concentration with the volume of ejaculate.

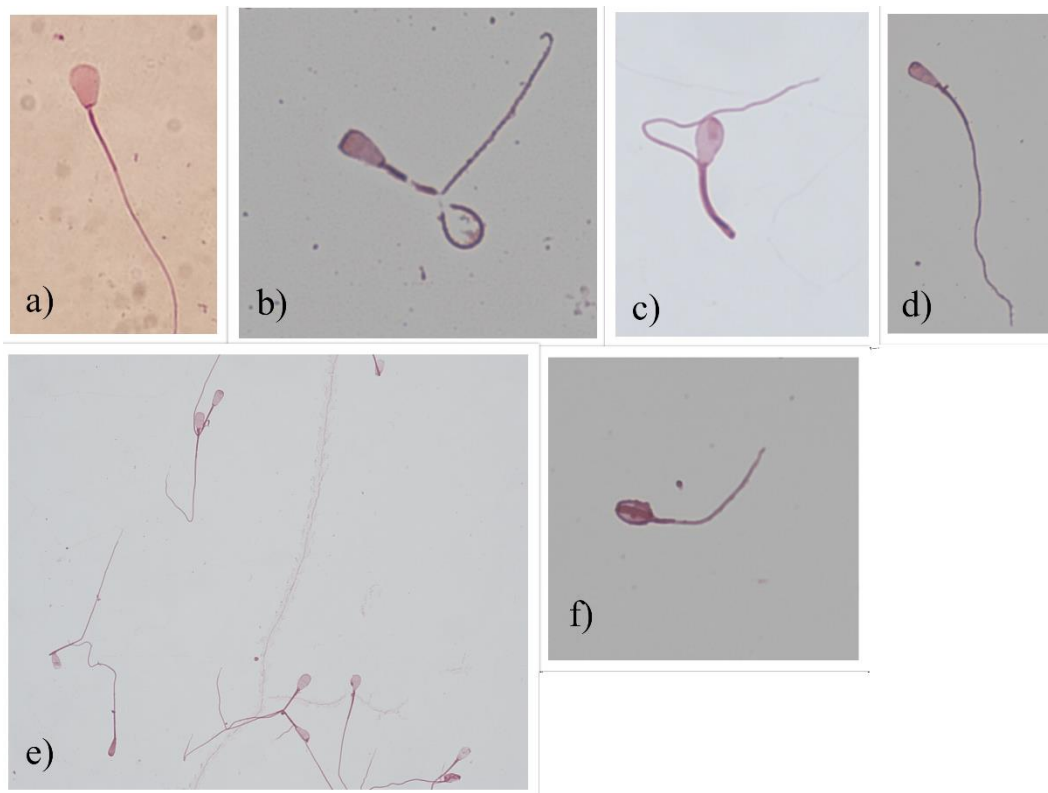
### 3.5.2. Spermatozoal morphology

The spermatozoal morphology was also examined by the Spermatology Laboratory in SLU.

The morphology was studied in two ways. Presence of pathological heads was examined through smear preparation and staining according to the method described by Williams (1920) and modified by Lagerlöf (1934) while the head-, midpiece and tail defects were examined in wet smears after mixing the semen sample with a formol-saline solution.

#### *Pathological heads*

Semen smears were prepared with a drop of fresh well-mixed undiluted semen sample on a glass slide. The smears were air-dried then stained with William's stain. 500 spermatozoa were counted using a phase contrast microscope under 1000 x magnification and the number of normal spermatozoa and spermatozoa with pathological heads (Pear shaped, narrow at the base, abnormal contour, undeveloped, narrow, variable size, abnormal detached heads and abaxial insertion of the tail) was recorded (see figure 1). The percentage of pathological heads was calculated (0-100%).



*Figure 1. Sperms with pathological heads: a) abaxial insertion; b) abnormal contour; c) pear-shaped head; d) narrow at base; e) variable sizes and f) undeveloped sperm cell.*

#### *Head, midpiece and tail defects*

Wet preparations of the semen were obtained by adding four to five drops of the fresh semen sample into 1.5 ml formol-saline solution until the solution became slightly cloudy. A drop of the mixed solution was placed on a microscope slide and

a cover slip was placed on top. The slide was examined with a phase contrast microscope under 1000 x magnification and 200 spermatozoa were counted. The number of spermatozoa with defects including knobbed acrosome, abnormal acrosome, detached head, nuclear vacuoles (diadem defect and craters), proximal cytoplasmic droplets, distal cytoplasmic droplets, defective midpiece, simple bent tail, coiled tail (under or around the head) and double bent tails were recorded (see figures 2-5). All defects of a spermatozoon were counted. The percentage of spermatozoa with respective defect and without defect was calculated (0-100%).

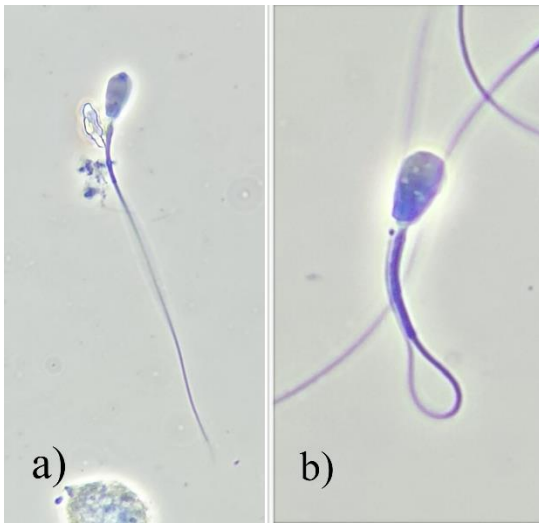

Figure 2. Sperms with a) knobbed acrosome and b) nuclear vacuoles (craters).

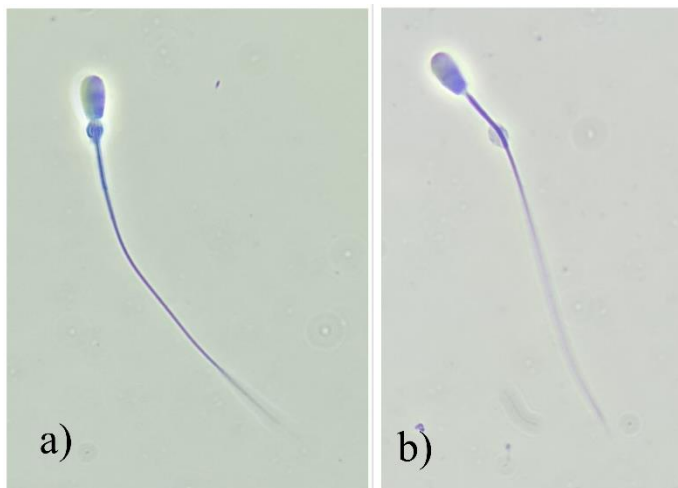


Figure 3. Sperms with cytoplasmic droplets: a) proximal droplet and b) distal droplet.



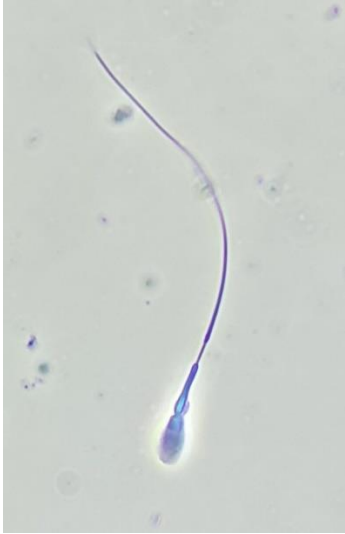

Figure 4. Midpiece defect - defective midpiece (Formol-saline solution).

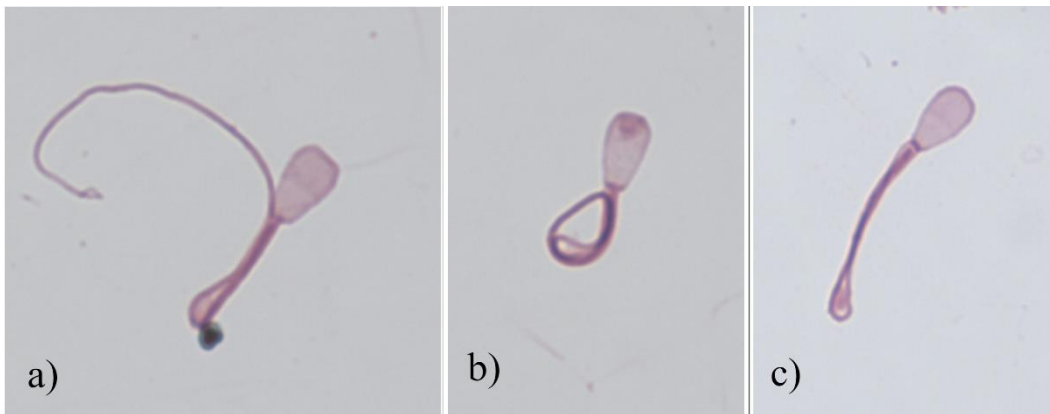


Figure 5. Sperms with tail defects: a) single bent tail; b) coiled tail and c) double bent tail.

The percentage morphologically normal spermatozoa (MNS) was calculated by subtracting the sum of percentage of spermatozoa without defect (counted by wet preparation with formol saline solution) and percentage of spermatozoa with distal cytoplasmic droplets (counted by wet preparation with formol saline solution) with the percentage of spermatozoa with pathological heads (counted with smear stained with William's stain). A percentage range of morphologically normal spermatozoa was then obtained. The percentage of MNS was calculated by adding the higher and the lower range and then divided by two.

The number of MNS was the product of MNS% and total number of sperm. The number of live MNS was the product of motility % and number of MNS.

### *Presence of other cells*

A smear with ridges was prepared by smearing four drops of semen sample on a glass slide and let dry. The smear was then stained using the Papanicolaou method and examined with microscope under 1000 x magnification to detect the presence of other cells (epithelial cells, boat-shaped cells, spermatogenic epithelial cells, degenerative pycnotic cells, leukocytes, other cells) (see figure 6). The presence of cells was categorized to none, sparse, weak, moderate, or strong.

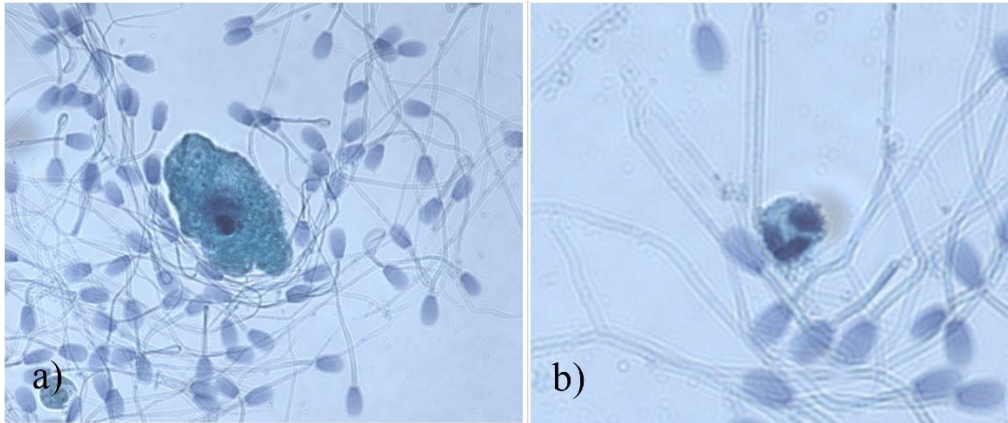


Figure 6. Presence of other cells in the semen sample: a) epithelial cell and b) neutrophil.

### 3.5.3. ALP

The ALP concentration of the seminal fluid from each semen sample was analysed as an epididymal marker as mentioned above.

## 3.6. Statistical analysis

The data was analysed with Minitab Software. Descriptive statistics were performed on all variables. Stepwise linear regression (alpha to enter and to remove was 0.2) was used to evaluate associations between semen quality (motility, total sperm count, percentage of morphologically normal sperm, number of morphologically normal sperm, prevalence of sperm defect) and other variables (age, BCS, weight, testicle size, testicle consistency, prostate examination, medical history, breeding history, location of sample collection etc). Binary logistic regression was used to analyse data between those who had been breeding with offspring and those who had been breeding but not resulting in offspring. Variables as motility, total sperm count, percentage of morphologically normal sperm, number of morphologically normal spermatozoa and prevalence of sperm defects were analysed to defect if any of them were associated with offspring. P-values <0.05 was considered significant.

## 4. Result

### 4.1. Background information

Background information of the participants are listed in table 1 and the distribution is displayed in figure 7. Semen samples from 65 male Bernese mountain dogs were collected between the period March to October 2020 (67 dogs participated in the project but from two dogs no semen sample was obtained). Two of the dogs (dog A and dog E) were sampled twice but only one sample from each (the second sample of dog A and the first sample of dog E) was included in the analysis. We collected semen samples from 23 of the 65 dogs in the university hospital while the other 42 dogs were sampled at other clinics (in total 14 clinics) and these samples were sent to the spermatology laboratory by post.

Table 1. Background information of the participants.

Variable	N	Mean	SE mean	StDev	Min	Median	Max
Age (month)	65	53.25	3.79	30.53	16.00	48.00	137.00
BCS (1-9)	64	5.01	0.10	0.80	3.00	5.00	7.00
Weight (kg)	65	49.45	0.62	4.96	35.00	50.00	58.10

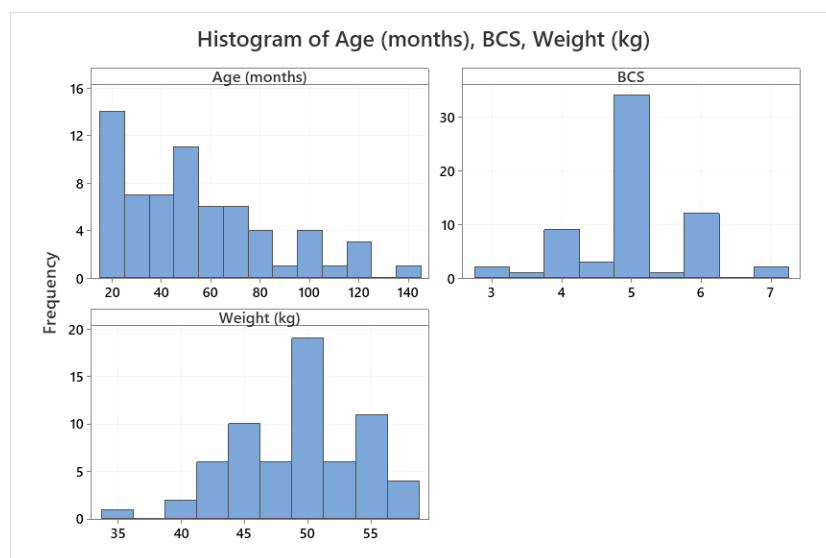


Figure 7. Histogram of age, Body Condition Score (BCS) and weight of the included dogs.

## 4.2. Medical history

Two dogs had problems with urination and one of those two dogs also had problems with defecation. For dogs that had received medical treatment, their history of medical treatment is shown in table 2.

Of the six dogs that were treated with hormones, five were treated with osaterone acetate (one was treated a week before the sample collection and the rest were treated more than two years ago) and one was treated with medroxyprogesterone acetate (treated seven months before sample collection).

For nine dogs treated with NSAID, two were treated with carprofen, two with robenacoxib, one with both carprofen and robenacoxib, one with meloxicam and three did not specify which substance they were treated with. Five of those nine dogs received treatment (three with an unspecific substance, one with robenacoxib, one with meloxicam and one with carprofen) within two months prior to semen collection.

Among those 43 dogs treated with ectoparasiticide within 12 months, 32 were treated with fluralaner, two with fipronil, two with afoxolaner, and seven with sarolaner.

*Table 2. History of medical treatment of the included dogs.*

	Hormonal treatment (n = 65)	NSAID	Antibiotic	Ectoparasiticide
Treated	6 (9.2%)	9 (13.9%)	6 (9.2%)	43 (66.2%)
Not treated	59 (90.8%)	56 (86.2%)	59 (90.1%)	22 (33.9%)

## 4.3. Examination of testicle and prostate

Testicle palpation was performed on 62 dogs, of which 39 dogs (62.9%) had normal consistency of both testicles, 23 dogs (37.1%) had at least one testicle with abnormal consistency (21 soft, one hard, and one lumpy). Age was found to have a positive association with abnormal consistency ( $p=0.043$ ) (see figure 8).

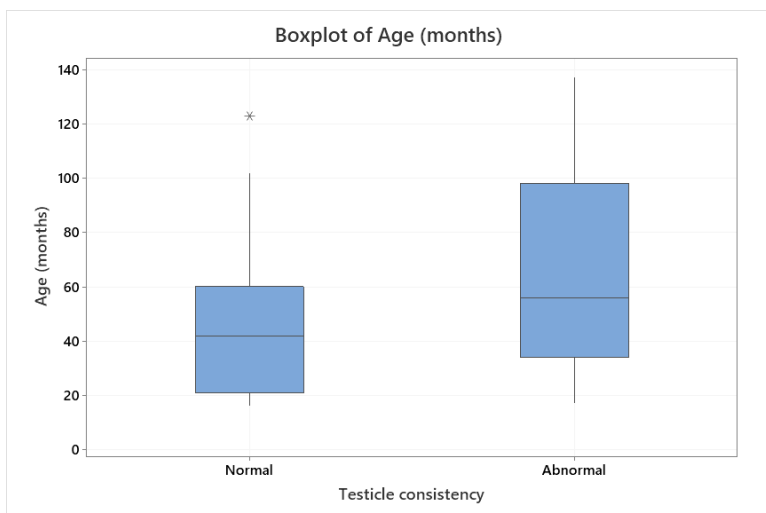


Figure 8. Boxplot of age and testicle consistency of the included dogs.

We obtained testicle measurements of 64 dogs. The size of the testicles is shown in table 3 and distribution shown in figure 9. One dog had extraordinarily wide scrotum (11cm) and total testicle volume of five dogs (including the dog with scrotal width 11cm) were larger than 108 cm<sup>3</sup>.

Table 3. Testicle size.

Variable	N	Mean	SE	StDev	Min	Media n	Max
Scrotal width (cm)	64	5.6	0.16	1.27	3.6	5.3	11.0
Total testicle volume (cm <sup>3</sup> )	64	47.93	3.85	30.79	17.99	38.03	161.79

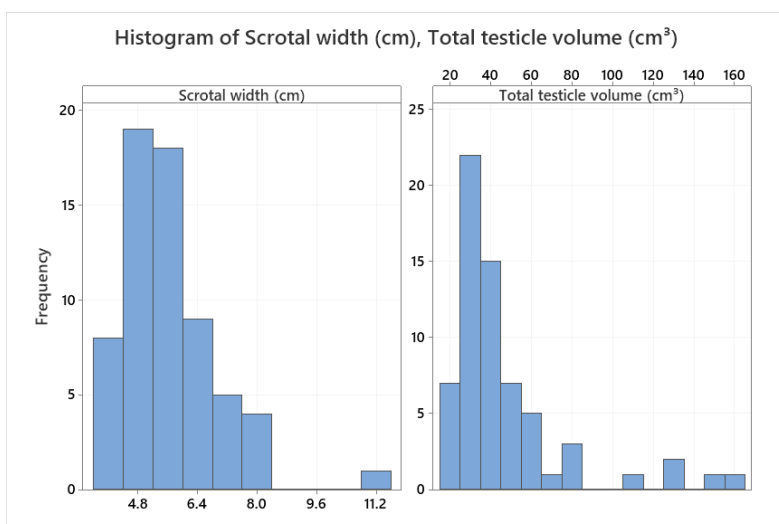


Figure 9. Histogram of scrotal width and testicle total volume of the included dogs.

The result of the prostate examination is shown below in table 4. The prostates of around half of the dogs could not be reached by rectal palpation and the small group

sizes of the dogs with signs of pain, asymmetric lobes, and abnormal consistency made it difficult to compare between groups. Therefore, the result of the prostate examination was not included in any analysis in this study.

Table 4. Result of prostate examination.

Prostate	N	Yes	No	Could not reach / evaluate
Signs of pain at palpation	64	2 (3.1%)	33 (50.0%)	30 (46.9%)
Symmetry between lobes	62	16 (25.8%)	7 (11.3%)	39 (62.9%)
Normal consistency	63	26 (41.3%)	2 (3.2%)	35 (55.6%)

## 4.4. Semen quality and sperm defects

### 4.4.1. Descriptive statistic

The semen quality and prevalence of sperm defects are listed in table 5 their distributions are shown in figure 10-11. Two semen samples were azoospermic, and both were from complete ejaculations (seminal ALP was 8325.9 U/L and 15624.5 U/L). Both dogs had soft consistency of their testicles on both sides. One sample had an extremely low sperm count (only 100 and 31 sperms found in the formol-saline solution and smear with William's stain respectively), this sample was from an incomplete ejaculation (seminal ALP was 104.6 U/L), and the testicles had normal consistency.

Among the 65 semen samples collected, 37 had normal colour, one was clear, 10 were yellow and 17 were red or brown. From two dogs more than 30 ml ejaculate was collected from the other dogs less than 21 ml was collected.

Regarding the total sperm number, 50 dogs (76.9%) had more than 300 million. Mean motility was lower than 70%, motility of 33 dogs (50.1%) were over 70%. The range of MNS % was wide and the distribution quite even, 22 dogs (33.9%) had more than 60% and eight dogs (12.3%) were higher than 80%. Among the 65 dogs, 40 (61.5%) of them had more than  $250 \times 10^6$  MNS in their ejaculate, of those 40 dogs 28 dogs (70%) had as sperm motility over 70%. Regarding the number of live MNS, 39 dogs (60%) had more than  $150 \times 10^6$  in their ejaculate.

The most dominating sperm defects were proximal droplets, single bent tail, and coiled tail (all over 10%). There were 16 dogs that had more than 20% proximal droplets, 11 dogs had more than 20% single bent tails and eight dogs had more than 20% coiled tails. Abnormal acrosomes and nuclear vacuoles were comparatively uncommon (both less 2%). Pathological heads was the sum of nine different

pathological head defects (listed above in Method and Materials) and the mean percentage among the participants was 7.21% and therefore it was deemed uncommon.

Two dogs had remarkably high percentage of detached head (28% and 34%) and both were older than 8.5 years. For vacuoles most of the dog had less than 3% except for three dogs (two had 8.3% and one had 15.5%). Only six dogs had more than 10 % spermatozoa with knobbed acrosomes.

*Table 5. Semen quality and prevalence of sperm defects.*

	N	Mean	SE Mean	StDev	Min	Median	Max
Volume of ejaculate (ml)	65	8.74	0.78	6.26	0.50	8.0	35.50
Motility (%)	65	61.43	3.29	26.50	0.00	70.00	98.00
Total number of sperm (10 <sup>9</sup> )	65	1.03	0.102	0.82	0.00	0.97	3.65
MNS (%)	65	46.78	3.23	26.05	0.00	48.00	87.50
Number of MNS (10 <sup>6</sup> )	65	522	61	491.8	0.0	353.4	1793.7
Number of live MNS (10 <sup>6</sup> )	65	389	49.8	401.3	0.0	273.5	1524.7
ALP (U/L)	64	189631	68492	547932	5	11218	3929118
Pathological heads (%)	63	7.21	0.75	5.93	0.00	5.80	37.90
Proximal droplets (%)	63	14.14	1.85	14.72	0.50	7.80	75.50
Detached heads (%)	63	3.01	0.70	5.57	0.00	1.00	34.00
Knobbed acrosomes (%)	63	3.69	0.76	6.05	0.00	1.50	37.50
Abnormal acrosomes (%)	63	0.06	0.025	0.20	0.00	0.00	1.00
Vacuoles (%)	63	1.11	0.30	2.41	0.00	0.50	15.50
Defective midpieces (%)	63	3.30	0.44	3.51	0.00	2.50	26.30
Single bent tails (%)	63	10.13	1.15	9.12	0.00	6.80	38.00
Coiled tails (%)	63	10.48	1.26	10.03	0.50	7.50	43.00
Double bent tails (%)	63	5.35	0.67	5.32	0.00	3.30	24.00

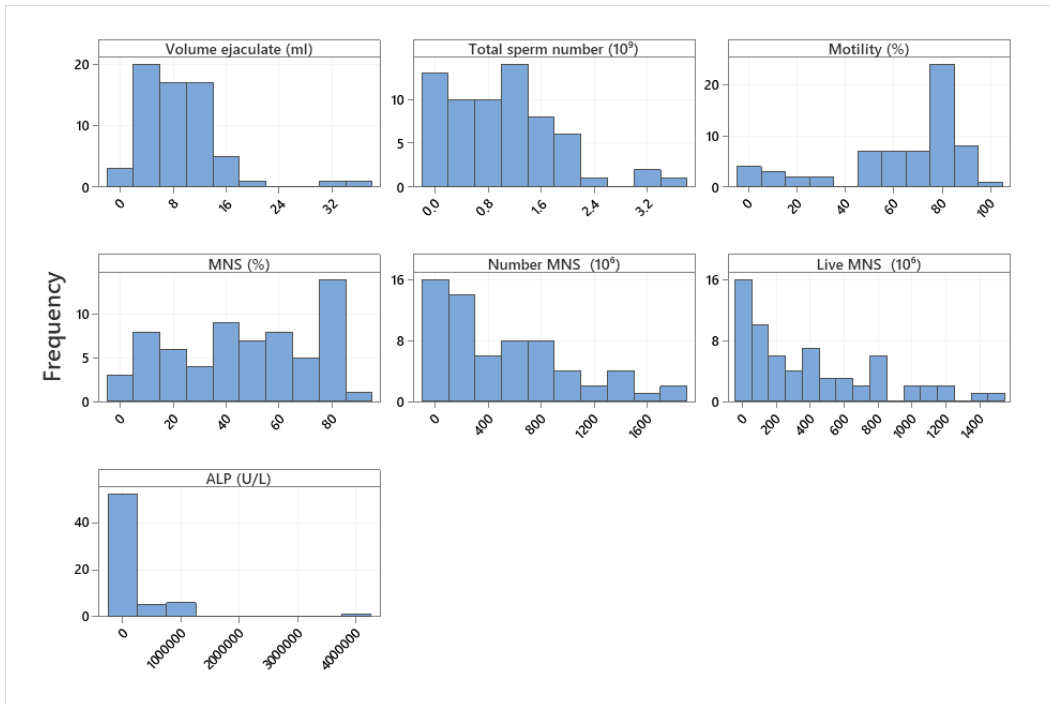


Figure 10. Histogram of ejaculate volume, motility, total sperm number, percentage of morphologically normal sperms (MNS), number of morphologically normal sperms (MNS), number of live morphologically normal sperms (MNS) and alkaline phosphatase (ALP).

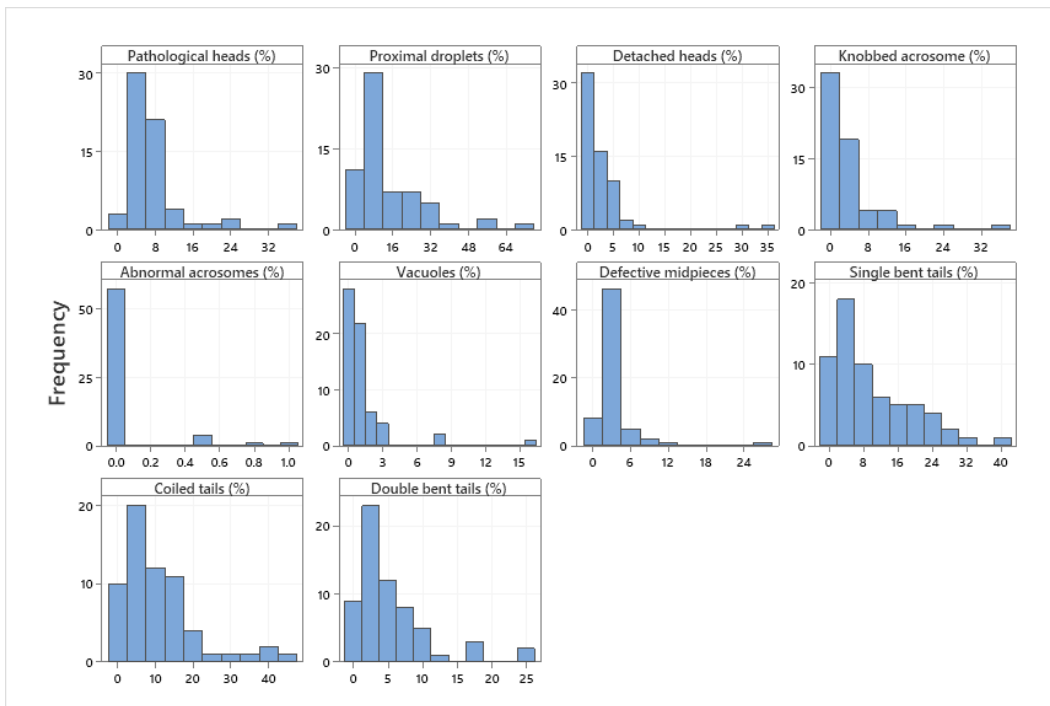


Figure 11. Histogram of sperm defects.

The presence of other cells in the semen sample is listed in table 6. The presence of these cell did not show any significant association with age, BCS, weight, testicle size or testicle consistency.



Table 6. Presence of cells in semen samples.

	N	Not present	A few to slight	Moderate to strong
Epithelial cells	63	12 (19.1%)	40 (63.5%)	11 (19.5%)
Spermatogenetic cells	63	35 (55.6%)	23 (36.5%)	5 (7.9%)
Degenerated, pyknotic cells	63	48 (76.2%)	13 (20.6%)	2 (3.2%)
Leucocytes	63	4 (6.4%)	34 (54.0%)	25 (39.7%)

#### 4.4.2. Association between variables

No significant associations were found between semen colour or testicle sizes (scrotal width or estimated volume of the testicle) and the sperm variables (total sperm numbers, motility, MNS %, number of MNS, percentage of respective sperm defects) nor dog variables (age, weight, BCS).

No significant associations were found between the total number of sperm or number of MNS and the dog variables (age, weight, BCS, testicle consistency and size). Motility was negatively associated with age ( $p=0.049$ ) (see figure 13). MSN % ( $p<0.001$ ) and number of live MNS ( $p=0.034$ ) were significantly lower in dogs with abnormal testicle consistency

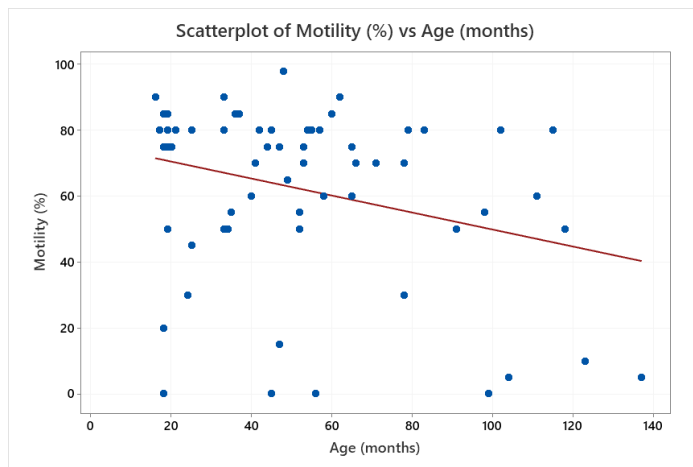


Figure 12. Scatterplot of Motility (%) vs Age (month) ( $p=0.0049$ ).

Dogs with abnormal testicle consistency had significantly higher percentage of spermatozoa with pathological heads ( $p=0.002$ ), proximal droplets ( $p=0.008$ ), knobbed acrosomes ( $p=0.008$ ) and vacuoles ( $p=0.004$ ) (see figure 13).

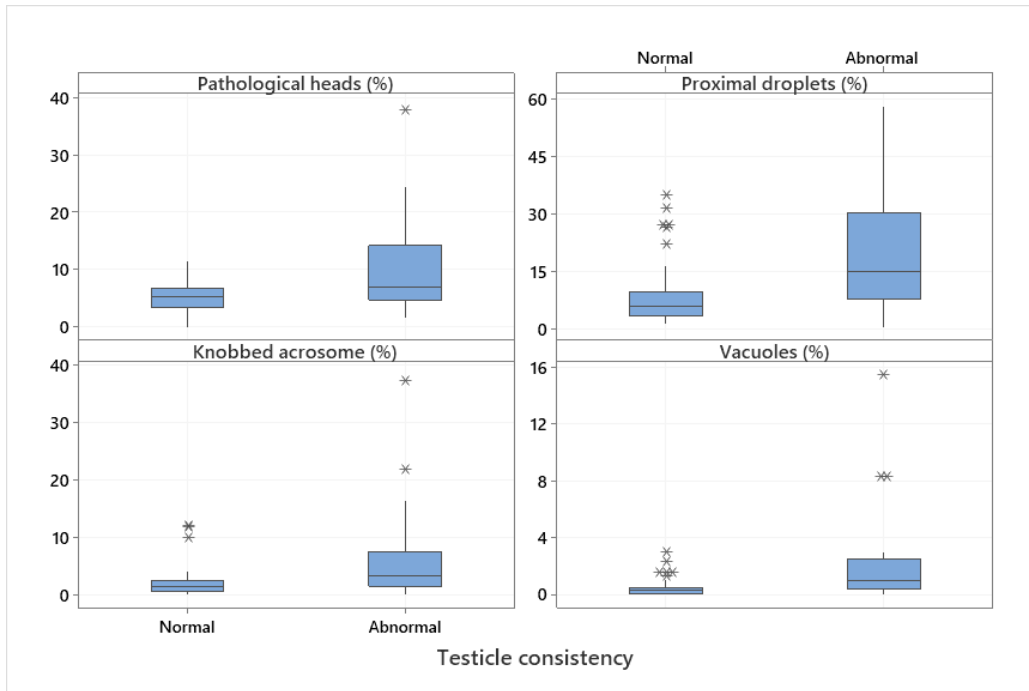


Figure 13. Boxplot of pathological heads ( $p=0.002$ ), proximal droplets ( $p=0.008$ ), knobbed acrosomes ( $p=0.008$ ) and vacuoles ( $p=0.004$ ) in dogs with normal and abnormal testicle consistency.

Percentage of proximal droplets ( $p=0.009$ ) and detached heads ( $p=0.004$ ) showed significant positive association with age (see figure 15). Percentage of detached heads ( $p=0.048$ ) showed positive association with sample collection at the university hospital (UDS).

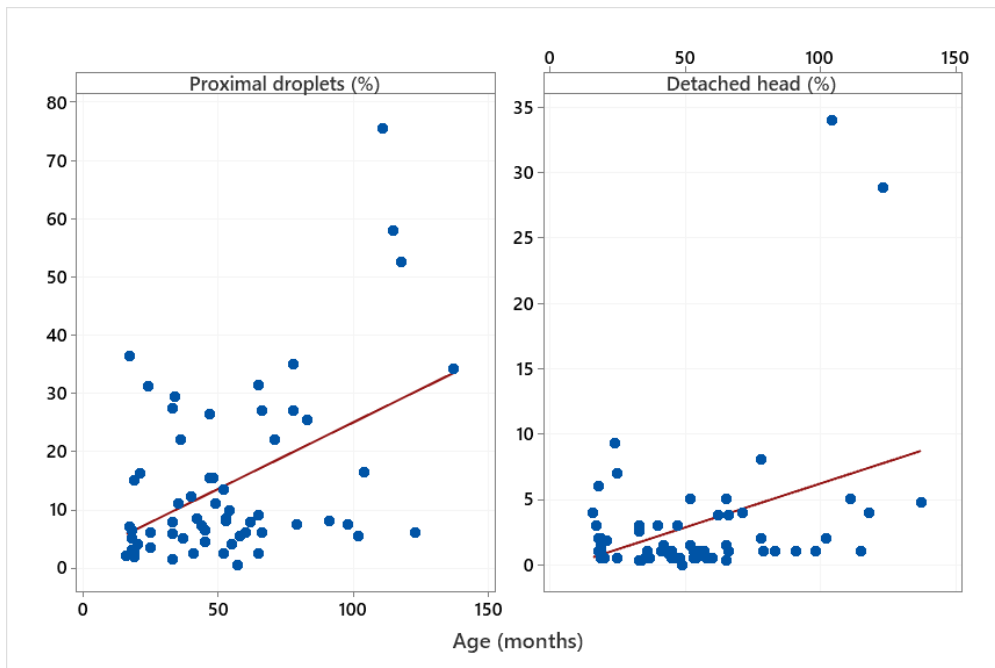


Figure 14. Scatterplot of proximal droplets ( $p=0.009$ ) and detached head ( $p=0.004$ ) vs Age (months).

Tail defects, abnormal acrosomes, and midpiece defects were not significantly associated with any variables included in this study.

## 4.5. Breeding history

Regarding the breeding history, 44 of the 65 dogs had been breeding. Among those 44 dogs, 36 had offspring and eight did not have offspring (semen samples from two of those eight dogs were azoospermic). The pregnancy rate was  $63.9\% \pm 5.6\%$  ( $n=36$ , range 0-100%) and mean litter size was  $4.6 \pm 0.3$  ( $n=36$ , range 1-11). Descriptive statistics for dogs with and without offspring is shown in table 8. Motility was significantly associated with the outcome “with offspring” ( $p=0.013$ ). The rest of the variables in table 8 did not show any significant association with the outcome “with offspring”.

Table 7. Descriptive statistics of dogs in breeding.

	Dogs with offspring					Dogs without offspring				
	N	Mean	StDev	Min	Max	N	Mean	StDev	Min	Max
Age (months)	36	61.2	31.9	17.0	137.0	8	61.5	23.0	24.0	99.0
BCS	36	4.9	0.9	3.0	7.0	8	5.4	0.5	5.0	6.0
Weight (kg)	36	49.6	4.9	39.5	58.0	8	50.4	6.6	35.0	56.0
Scrotal width (mm)	35	5.5	1.2	3.6	8.0	8	6.0	2.2	3.9	11.0
Testes total volume (cm <sup>3</sup> )	36	46.9	28.7	20.0	154.9	8	49.3	46.5	18.0	161.8
Total number sperm (10 <sup>9</sup> )	36	1.2	0.8	0.03	3.2	8	0.6	0.7	0.0	1.8
Motility (%)	36	67.0	22.4	5.0	98.0	8	40.0	29.6	0.0	75.0
MNS (%)	36	49.7	25.9	5.0	87.5	8	22.1	21.1	0.0	55.5
Number of MNS (10 <sup>6</sup> )	36	579	508	4.5	1793.7	8	191.9	242.3	0.0	628.3
Number of live MNS (10 <sup>6</sup> )	36	429	405.8	0.8	1542.7	8	126.5	178.6	0.0	439.8
Pathological head (%)	36	7.3	4.5	2.4	24.4	6	11.2	13.1	5.0	37.9
Proximal droplets (%)	36	15.2	16.0	0.5	75.5	6	21.3	13.8	2.5	35.0
Detached head (%)	36	3.5	7.1	0.0	34.0	6	4.6	3.5	0.5	9.3
Knobbed acrosome (%)	36	3.3	4.0	0.0	16.5	6	4.8	8.5	0.0	22.0
Abnormal acrosome (%)	36	0.1	0.2	0.0	1.0	6	0.1	0.2	0.0	0.5
Vacuoles (%)	36	1.5	3.1	0.0	15.5	6	0.2	0.3	0.0	0.5
Defective midpiece (%)	36	3.8	4.3	0.0	26.3	6	4.3	3.6	2.0	11.5
Single bent tails (%)	36	9.7	10.2	0.0	38.0	6	13.1	6.9	5.5	21.5
Coiled tails (%)	36	9.8	10.3	0.5	43.0	6	15.7	11.9	7.0	39.0
Double bent tails (%)	36	5.9	6.3	0.0	24.0	6	6.7	5.4	2.5	17.0

Among those 44 dogs that had been breeding, 16 had mated within two months of the sample collection and 13 of these 16 matings had result in confirmed pregnancy (the outcome of the three other matings were not confirmed yet). The descriptive statistics of those 13 dogs and their sperm quality are shown in table 9. Mean litter size of the pregnancies resulting from matings within two months of 12 of these 13 dogs was 3.8 puppies per litter (range 1-6) (information of pregnancy outcome was missing from one dog). Among those 13 dogs only one dog was over five years old (98-month-old), and all of them were in ideal weight (4-5 in BCS). Four of the 13 dogs had at least one testicle with abnormal consistency, the mean litter size for these four dogs was 2 (range 1-3).

*Table 8. Descriptive statistics of the 13 dogs who had mated within two months of sample collection with confirmed pregnancy.*

	N	Mean	StDev	Min	Median	Max
Age (months)	13	38.4	22.5	17.0	33.0	98.0
BCS	13	4.7	0.5	4.0	5.0	5.0
Weight (kg)	13	49.8	4.3	40.0	50.5	55.0
Total sperm number (10 <sup>9</sup> )	13	1.2	0.5	0.03	1.2	2.4
Motility (%)	13	73.3	16.4	45.0	80.0	98
MNS (%)	13	58.2	21.9	18.5	59.5	81.5
Number MNS (10 <sup>6</sup> )	13	644	399	21.5	713	1335
Number of live MNS (10 <sup>6</sup> )	13	483	340.3	21.0	394.1	1068.0
Pathological heads (%)	13	6.4	3.1	3.4	5.4	15.4
Proximal droplets (%)	13	10.6	9.2	0.5	8.5	36.3
Detached heads (%)	13	1.9	1.8	0.3	1.5	7.0
Knobbed acrosome (%)	13	2.5	4.6	0.0	1.0	16.5
Abnormal acrosomes (%)	13	0.04	0.1	0.0	0.0	0.5
Vacuoles (%)	13	2.1	4.2	0.0	0.5	15.5
Defective midpieces (%)	13	4.7	6.8	0.0	2.5	26.3
Single bent tails (%)	13	10.0	11.4	1.5	4.0	38.0
Coiled tails (%)	13	6.0	4.8	0.5	5.0	14.0
Double bent tails (%)	13	5.3	6.4	0.0	2.8	24.0

## 5. Discussion

The present study was, to my knowledge, the first study to focus solely on the semen quality of the BMD. A general picture of the semen quality of the Swedish population was able to obtain with the 65 samples obtained. Several associations between semen quality and traits of the dogs were also found. The aims of the study were achieved.

### 5.1. Background information

The mean age of the participants was 53.3 months old with a range from 16 to 137 months. Most of the dogs were under five years old (66.2 %) and only nine dogs (20.5%) were older than seven years. The study conducted by Tesi *et al.* (2018) categorized dogs under two years old as “young”, two to seven years old as “adult” and over seven years old as “old”, however, as the median age for BMD was around 7-7.7 years (Proschowsky *et al.* 2003; Klopfenstein *et al.* 2016) these cut-off points for age-grouping might not be applicable for this breed and a lower cut-points would probably be more fitting for the BMDs.

Mean and median BCS was 5 and 46/64 dogs had their estimated BCS as 4 or 5 which showed that about 72% of the dogs had ideal weight. BCS did not show any significant association with any of the variables related to semen quality. It would be interesting to explore further if BCS would have an influence on semen quality if more overweight or underweight dogs participated.

Interestingly 66.2% of the dogs received ectoparasiticide treatment and it thus seemed to be a popular practice among BMD owners here in Sweden.

Regarding examination of the prostate, it was difficult to reach and examine the organ and no statistical comparisons were performed. For future studies it would be useful to perform ultrasound examination on the prostate to obtain an objective assessment of size, symmetry, and other changes of the organ.

## 5.2. Semen quality

### 5.2.1. Semen quality

The volume of the ejaculates collected varied as some samples were collected only from fraction two while other contained more than one fraction.

Around half of the participating dogs had total motility over 70 % which is the cut-off point for normal motility according to several publications (Johnston 1991; Freshman 2002; Feldman 2004). A significant negative association was found between age and motility in the present study. Previously, there have been inconsistent findings of the influence of age on motility (Hesser *et al.* 2017; Bhanmeechao *et al.* 2018; Brito *et al.* 2018; Tesi *et al.* 2018). According to Saacke (2008) and Saacke *et al.* (1998, 2000) impaired motility can be regarded as a compensable semen trait, and be counteracted by increased number of morphologically normal and motile sperm. The sperm tail is the motor unit of the spermatozoa. In the present study there was no association between age and any of the tail defects that could have explained the decreased motility. The underlying cause of the negative influence of age on motility is yet to be discovered. For BMD owners who wish to breed their dogs, it would be beneficial to breed them early on once they have reached sexual maturity and have passed the required health control programme by the breed standard, as it was shown in the present study that motility of the spermatozoa decreased with increasing age and the percentages of two sperm defects (proximal droplets and detached heads) also increased with age.

The majority of the dogs (50 dogs, 76.9%) had more than 300 million spermatozoa in their ejaculate and fell within the normal range (300 million to 2 billion) (Johnston 1991; Root Kustritz 2007). Larger dogs produce more spermatozoa than smaller dogs since they have more testicular tissue (Johnston *et al.* 2001; Tesi *et al.* 2018). However, in the present study, neither scrotal width nor the estimated total volume of the testicles showed any significant association with the total number of sperm. As the sample collection and examination of the testicle was performed in 15 different clinics, the coherence of testicle measurement could be reduced. Weight was not associated with total sperm number. In the present study only dogs of the same breed were included, if dogs with different breeds of variable sizes had been included a difference in total sperm count between different weight groups could possibly have been more prominent as shown in the study by Tesi *et al.* (2018). The mean total number of sperm in this study was  $1.2 \pm 0.21 \times 10^9$ , in Tesi *et al.*'s study (2018) the mean total sperm number of their large dog group (>40kg, n=31) was  $692.6 \times 10^6$ . Mean total sperm number of the present study was thus almost double as much as their result and 40 of 65 dogs (61.5%) had total sperm number higher than  $692.6 \times 10^6$ .

The mean MNS % was quite low (46.79%), much lower than the normal value (80%) according to Johnston (1991). Only 8 dogs (12.3%) had MNS % over 80%. Additionally, only 22 dogs (33.9%) had MNS % over 60% and according to Oettlé (1993), fertility can be adversely affected when MNS % is below 60. In Tesi *et al.*'s study (2018), the mean MNS % for dogs with offspring after AI was 64.9% and 20 dogs in the present study had a higher MNS %. In the present study, it was demonstrated that MNS % was significantly lower and four sperm defects were higher in dogs with abnormal testicle consistency.

The number of MNS was not significantly associated with any other variables in the present study. The number of MNS has been described to significantly influence the pregnancy rate (Mickelsen *et al.* 1993) and it was shown that ejaculates containing more than 250 million MNS yielded a pregnancy rate over 80% with AI. Among the 65 dogs in the present study, 40 (61.5%) had more than 250 million MNS in their ejaculates and these samples, theoretically, should be able to yield pregnancy if used for AI. Among those 40 dogs, 28 also had motility over 70%, these 28 dogs (43%) were likely to be fertile. However, pregnancy can also still be achieved with MNS lower than 250 million as the recommended number of live normal sperm for AI is minimum 150 to 200 million (Linde-Forsberg 1991; Mason 2017, 2018). In the present study, 39 dogs (60%) had a number of live MNS higher than 150 million which reflected that majority of the participants fulfilled the minimum requirement of sperm dose for AI.

### 5.2.2. Specific defects

Abnormal testicle consistency, age and clinic of semen collection were the only factors that showed significant associations with the prevalence of sperm defects. Percentage of pathological heads, proximal droplets, knobbed acrosomes, and vacuoles were the defects that were significantly associated with the abnormal testicle consistency. Interestingly, all of the four defects are classified as primary defects and major defects (Blom 1973; Barth & Oko 1989 see Kolster 2018; Johnston 1991; Freshman 2001, 2002; Feldman 2004; Chenoweth 2005). That they are primary defects means that they arise during spermatogenesis. Interestingly, age was found to be positively associated with abnormal testicle consistency in this study, suggesting a higher risk of testicular degeneration with increasing age. A recent study of age-related changes testicular microanatomy in dogs showed that collagen content in the testicular interstitium in older dogs increased which indicated gradual deterioration of testicular tissue (Tesi *et al.* 2020). It is logical that spermatogenesis is adversely affected when the structure and consistency of the testicle deteriorates, leading to the increased occurrence of primary defects. As they are also major defects, the increased prevalence of these defects would negatively

affect fertility of the dogs. The result of this study suggests that abnormal consistency of testicles might have a negative impact on fertility through increasing the prevalence of major defects. Palpation of testicles and the examination of consistency is subjective and therefore further studies will be needed to see if the same result and association is generated. For BMD owners who wish to breed their dogs, if they suspect an abnormality of their dogs' testicles it would also be advisable to perform semen analysis before mating.

Tesi *et al.* (2018) claimed that a decrease in the volume and consistency of the testes were noted in azoospermic dogs. Interestingly, the two azoospermic semen samples were obtained from dogs with soft consistency of both testicles. However, no significant difference in total sperm number was found between dogs with normal and abnormal testicle consistency (at least one testicle with abnormal consistency) in the present study. As mentioned above, abnormal consistency can be indicative of lower MNS % and higher presence of certain sperm defects. Palpation of the testicles is a simple examination to be performed and therefore it would be rather easy to incorporate it into most studies of male fertility. By doing so, the connection between testicle consistency and sperm quality can be further investigated.

Proximal droplets was the most common sperm defect among our participants and the percentage of this defect was positively associated with age, consistent with the findings of Tesi *et al.* (2018) and Brito *et al.* (2018). Proximal droplets is a major defect (Blom 1973; Johnston 1991; Freshman 2001; Feldman 2004; Kolster 2018). With increasing age, the prevalence of these defects will increase, which in turn will possibly impair the reproductive capacity of the dogs. Previous case reports of proximal droplets in dogs (Plummer *et al.* 1987; Peña *et al.* 2007) have suggested that this defect impairs the spermatozoa's ability to capacitate (Peña *et al.* 2007). In boars, it was found that the defect is negatively correlated to pregnancy rate and litter size (Waberski *et al.* 1994). As proximal droplets was the most common defect among the BMD in this study its impact on the fertility of this breed should be studied further.

Age also showed a positive association with detached heads. The detachment of the headpiece can happen during spermiogenesis (as a primary defect) (Chenoweth 2005), during epididymis passage (Kawakami *et al.* 2005), and also during semen collecting and manipulation of the sample (Chłopik & Wysokińska 2020). The positive association between age and detached head indicated pre-sampling detachment.

Age did not show any significant association with the proportion of normal spermatozoa in the present study, in contrast to previous studies mentioned (Rijsselaere *et al.* 2007; Hesser *et al.* 2017; Bhanmeechao *et al.* 2018; Brito *et al.* 2018; Tesi *et al.*



*al.* 2018). This might be due to the fact that age only showed significant associations with two (proximal droplets and detached heads) of the ten defects counted in the present study and therefore might not have a notable influence on the overall percentage of MNS.

If sample collecting location was an influencing factor of the semen sample quality, the secondary defects should differ between collectors as secondary defects can arise during sample collection, handling and transportation. In the present study the difference between samples collected as UDS and other clinics was the transportation of samples by post. No significant difference was found between samples collected at the university hospital (UDS) and 14 other clinics regarding abnormal acrosomes and single bent tails but only detached heads. This suggested that transportation of sample might not have a negative influence on the sample quality in the present study.

### 5.3. Breeding dogs

For dogs that had been breeding, even though significant difference of motility was found between dogs with and without offspring, this association could be potentially stronger if the sample collection took place near the dogs' last mating session.

For those 13 dogs who mated within two months of sample collections and pregnancy was confirmed, the lowest sperm total sperm number among them was 30 million which was much lower than the normal range according to Johnston (1991) and Root Kustritz (2007). These dogs were able to reproduce even when the lowest motility among them was 45% and lowest MNS % was 18.5%. Surprisingly the lowest number of live MNS was 21 million which was much lower than the recommended dose for AI (Linde-Forsberg 1991; Mason 2017, 2018). These results showed that pregnancy was still achievable with semen of inferior quality and this showed the difficulties of assessment of reproductive capacities of dogs as the fertility might not be completely accounted for by the semen quality.

The male side only accounts for one side of the reproductive outcome, the female is equally important in the equation. For future studies, it would be desirable to collect semen samples within two months of the dog's latest mating with a female known to be fertile if one attempts to study associations between semen quality and the breeding outcome.

## 5.4. Conclusion

The most important findings in this study were the prevalence and distribution of different sperm defects among the participants, and the association between certain defects and semen quality with age and testicle consistency. Among the 65 dogs participating in the study, 39 (60%) had over 150 million live MNS (the minimum recommended dose for AI) and therefore these dogs were likely to be fertile. To my knowledge this is the first study conducted with sole focus on the semen and sperm quality of the Bernese mountain dog breed and hopefully it contributes to better understanding of the reproductive capacity of this breed.

## Reference list

- Agria Djurförsäkring (2018). *Berner Sennenhund Agria Breed Profiles Veterinärvård 2011-2016*
- Amann, R.P., Hay, S.R. & Hammerstedt, R.H. (1982). Yield, characteristics, motility and cAMP content of sperm isolated from seven regions of ram epididymis. *Biology of Reproduction*, 27 (3), 723–733. <https://doi.org/10.1095/biolreprod27.3.723>
- Amann, R.P., Seidel, G.E. & Mortimer, R.G. (2000). Fertilizing potential in vitro of semen from young beef bulls containing a high or low percentage of sperm with a proximal droplet. *Theriogenology*, 54 (9), 1499–1515
- Angrimani, D.S.R., Losano, J.D.A., Lucio, C.F., Veiga, G.A.L., Pereda, M.C., Nichi, M. & Vannucchi, C.I. (2014). Role of residual cytoplasm on oxidative status during sperm maturation in dogs. *Animal Reproduction Science*, 151 (3), 256–261
- Aquino-Cortez, A., Pinheiro, B.Q., Silva, H.V.R., Lima, D.B.C., Silva, T.F.P., Souza, M.B., Viana, D.A., Júnior, F.X., Evangelista, J., Brandão, F.Z. & Silva, L.D.M. (2017). Serum testosterone, sperm quality, cytological, physicochemical and biochemical characteristics of the prostatic fraction of dogs with prostatomegaly. *Reproduction in Domestic Animals*, 52 (6), 998–1003
- Axnér, E., Holst, B.S. & Linde-Forsberg, C. (1998). Morphology of spermatozoa in the cauda epididymidis before and after electroejaculation and a comparison with ejaculated spermatozoa in the domestic cat. *Theriogenology*, 50 (6), 973–979. [https://doi.org/10.1016/S0093-691X\(98\)00200-3](https://doi.org/10.1016/S0093-691X(98)00200-3)
- Axnér, E., Linde-Forsberg, C. & Einarsson, S. (1999). Morphology and motility of spermatozoa from different regions of the epididymal duct in the domestic cat. *Theriogenology*, 52 (5), 767–778
- Barth, A.D. (1986). The knobbed acrosome defect in beef bulls. *The Canadian Veterinary Journal*, 27 (10), 379–384
- Barth, A.D. & Oko, R.J. (1989). *Abnormal Morphology of Bovine Spermatozoa*. Ames: Iowa State University Press. <https://www.cabdirect.org/cabdirect/abstract/19900178378> [2020-11-06]
- Bhanmeechao, C., Srisuwatanasagul, S., Prapaiwan, N. & Ponglowhapan, S. (2018). Reproductive aging in male dogs: The epididymal sperm defects and expression of androgen receptor in reproductive tissues. *Theriogenology*, 108, 74–80

- Blom, E. (1966). A new sterilizing and hereditary defect (the 'Dag Defect') located in the bull sperm tail. *Nature*, 209 (5024), 739–740
- Blom, E. (1973). The ultrastructure of some characteristic sperm defects and a proposal for a new classification of the bull spermogram. *Nordisk Veterinaermedicin*, 25 (7), 383–391
- Brito, M.M., Angrimani, D.S.R., Lucio, C.F. & Vannucchi, C.I. (2018). A case trial study of the effect of ageing on fresh and post-thaw sperm in dogs. *Andrologia*, 50 (9), e13123
- Chenoweth, P.J. (2005). Genetic sperm defects. *Theriogenology*, 64 (3), 457–468
- Chłopik, A. & Wysokińska, A. (2020). Canine spermatozoa - What do we know about their morphology and physiology? An overview. *Reproduction in Domestic Animals*, 55 (2), 113–126
- Cooper, T.G. (2005). Cytoplasmic droplets: the good, the bad or just confusing? *Human Reproduction*, 20 (1), 9–11
- Dahlbom, M., Andersson, M., Lahdetie, J., Vierula, M. & Alanko, M. (1997). Probable spermatozoal diploidy in the semen of a golden retriever. *Andrologia*, 29 (1), 49–55
- Davies, M. (1996). *Canine and Feline Geriatrics*. Oxford: Blackwell Science. (Library of veterinary practice)
- Enciso, M., Cisale, H., Johnston, S.D., Sarasa, J., Fernández, J.L. & Gosálvez, J. (2011). Major morphological sperm abnormalities in the bull are related to sperm DNA damage. *Theriogenology*, 76 (1), 23–32
- Fekonja, N., Štrus, J., Tušek Žnidarič, M., Knez, K., Vrtacnik Bokal, E., Verdenik, I. & Virant-Klun, I. (2014-04-09). Clinical and structural features of sperm head vacuoles in men included in the in vitro fertilization programme. *BioMed Research International*. [Research Article]. <https://doi.org/10.1155/2014/927841>
- Feldman, E.C. (2004). *Canine and Feline Endocrinology and Reproduction*. 3rd ed. Philadelphia: Saunders.
- Flores, R.B., Angrimani, D.S.R., Rui, B.R., Brito, M.M., Abreu, R.A. & Vannucchi, C.I. (2017). The influence of benign prostatic hyperplasia on sperm morphological features and sperm DNA integrity in dogs. *Reproduction in Domestic Animals*, 52 (S2), 310–315
- Frenette, G., Dubé, J.Y. & Tremblay, R.R. (1986). Origin of alkaline phosphatase of canine seminal plasma. *Archives of Andrology*, 16 (3), 235–241
- Freshman, J.L. (2001). Clinical management of the subfertile stud dog. *Veterinary Clinics of North America: Small Animal Practice*, 31 (2), 259–269
- Freshman, J.L. (2002). Semen collection and evaluation. *Clinical Techniques in Small Animal Practice*, 17 (3), 104–107

- Gubbels, Ed.J., Scholten, J., Janss, L. & Rothuizen, J. (2009). Relationship of cryptorchidism with sex ratios and litter sizes in 12 dog breeds. *Animal Reproduction Science*, 113 (1), 187–195
- Hesser, A., Darr, C., Gonzales, K., Power, H., Scanlan, T., Thompson, J., Love, C., Christensen, B. & Meyers, S. (2017). Semen evaluation and fertility assessment in a purebred dog breeding facility. *Theriogenology*, 87, 115–123
- Inaba, K. & Mizuno, K. (2016). Sperm dysfunction and ciliopathy. *Reproductive Medicine and Biology*, 15 (2), 77–94
- Johnston, S.D. (1991). Performing a complete canine semen evaluation in a small animal hospital. *Veterinary Clinics of North America: Small Animal Practice*, 21 (3), 545–551
- Johnston, S.D., Root Kustritz, M.V. & Olson, P.S. (2001). *Canine and Feline Theriogenology*. Philadelphia, Pa. ; Saunders.
- Kawakami, E., Ozawa, T., Hirano, T., Hori, T. & Tsutsui, T. (2005). Formation of detached tail and coiled tail of sperm in a beagle dog. *The Journal of Veterinary Medical Science*, 67 (1), 83–85
- Khan, F.A., Gartley, C.J. & Khanam, A. (2018). Canine cryptorchidism: An update. *Reproduction in Domestic Animals*, 53 (6), 1263–1270
- Klopfenstein, M., Howard, J., Rossetti, M. & Geissbühler, U. (2016). Life expectancy and causes of death in Bernese mountain dogs in Switzerland. *BMC Veterinary Research*, 12. <https://www.ncbi.nlm.nih.gov/pmc/articles/PMC4960675/> [2020-09-02]
- Kolster, K.A. (2018). Evaluation of canine sperm and management of semen disorders. *Veterinary Clinics of North America: Small Animal Practice*, 48 (4), 533–545
- Laflamme, D. (1997). Development and validation of a body condition score system for dogs. *Canine Practice*, 22 (4), 10–15
- Lagerlöf, N. (1934). Morphologische Untersuchungen über Veränderungen im Spermabild und in den Hoden bei Bullen mit verminderter oder aufgehobener Fertilität. *Acta Pathologica et Microbiologica Scandinavica*, 19 (Suppl)
- Lasley, J.F. & Bogart, R. (1944). A comparative study of epididymal and ejaculated spermatozoa of the boar. *Journal of Animal Science*, 3 (4), 360–370. <https://doi.org/10.2527/jas1944.34360x>
- Linde-Forsberg, C. (1991). Achieving canine pregnancy by using frozen or chilled extended semen. *Veterinary Clinics of North America: Small Animal Practice*, 21 (3), 467–485
- Linde-Forsberg, C. (2001). Biology of reproduction of the dog and modern reproductive technology. In: Ruvinsky, A. & Sampson, J. (eds.) *The Genetics of the Dog*. Wallingford, Oxon, UK ; CABI Pub, 401–430

- Luño, V., Martínez, F., Borobia, M., Hörndler, C. & Gil, L. (2020). Sperm tail defects and abnormal testicular blood flow in a beagle dog: a case report. *Topics in Companion Animal Medicine*, 38, 100371
- Ma, J., Wu, L., Zhou, Y., Zhang, H., Xiong, C., Peng, Z., Bao, W., Meng, T. & Liu, Y. (2019). Association between BMI and semen quality: an observational study of 3966 sperm donors. *Human Reproduction (Oxford, England)*, 34 (1), 155–162. <https://doi.org/10.1093/humrep/dey328>
- Mason, S.J. (2017). A retrospective clinical study of endoscopic-assisted transcervical insemination in the bitch with frozen–thawed dog semen. *Reproduction in Domestic Animals*, 52 (S2), 275–280. <https://doi.org/10.1111/rda.12864>
- Mason, S.J. (2018). Current review of artificial insemination in dogs. *Veterinary Clinics of North America: Small Animal Practice*, 48 (4), 567–580. <https://doi.org/10.1016/j.cvsm.2018.02.005>
- Memon, M.A. (2007). Common causes of male dog infertility. *Theriogenology*, 68 (3), 322–328
- Merton, H. (1940). Studies on reproduction in the albino mouse. II. Contributions on the maturation of the sperm cells. *Proceedings of the Royal Society of Edinburgh*, 59, 145–152. <https://doi.org/10.1017/S0370164600012232>
- Mickelsen, W.D., Memon, M.A., Anderson, P.B. & Freeman, D.A. (1993). The relationship of semen quality to pregnancy rate and litter size following artificial insemination in the bitch. *Theriogenology*, 39 (2), 553–560
- Mitchell, J.R., Senger, P.L. & Rosenberger, J.L. (1985). Distribution and retention of spermatozoa with acrosomal and nuclear abnormalities in the cow genital tract. *Journal of Animal Science*, 61 (4), 956–967
- Munkittrick, T.W., Nebel, R.L. & Saacke, R.G. (1992). Accessory sperm numbers for cattle inseminated with protamine sulfate microcapsules. *Journal of Dairy Science*, 75 (3), 725–731
- Oettlé, E.E. (1993). Sperm morphology and fertility in the dog. *Journal of Reproduction and Fertility. Supplement*, 47, 257–260
- Olar, T.T., Amann, R.P. & Pickett, B.W. (1983). Relationships among testicular size, daily production and output of spermatozoa, and extragonadal spermatozoal reserves of the dog. *Biology of Reproduction*, 29 (5), 1114–1120
- Overstreet, J.W., Cooper, G.W. & Katz, D.F. (1978). Sperm transport in the reproductive tract of the female rabbit: II. The sustained phase of transport. *Biology of Reproduction*, 19 (1), 115–132
- Peña, A.I., Barrio, M., Becerra, J.J., Quintela, L.A. & Herradón, P.G. (2007). Infertility in a dog due to proximal cytoplasmic droplets in the ejaculate: Investigation of the significance for sperm functionality in vitro. *Reproduction in Domestic Animals*, 42 (5), 471–478

- Peters, M.A.J., de Rooij, D.G., Teerds, K.J., van der Gaag, I. & van Sluijs, F.J. (2000). Spermatogenesis and testicular tumours in ageing dogs. *Journal of Reproduction and Fertility*, 120 (2), 443–452
- Petrunkina, A.M., Gehlhaar, R., Drommer, W., Waberski, D. & Topfer-Petersen, E. (2001). Selective sperm binding to pig oviductal epithelium in vitro. *Reproduction*, 121 (6), 889–896
- Plummer, J.M., Watson, P.F. & Allen, W.E. (1987). A spermatozoal midpiece abnormality associated with infertility in a Lhasa apso dog. *Journal of Small Animal Practice*, 28 (8), 743–751
- Proschowsky, H.F., Rugbjerg, H. & Ersbøll, A.K. (2003). Mortality of purebred and mixed-breed dogs in Denmark. *Preventive Veterinary Medicine*, 58 (1), 63–74
- Ramaraju, G.A., Teppala, S., Prathigudupu, K., Kalagara, M., Thota, S., Kota, M. & Cheemakurthi, R. (2018). Association between obesity and sperm quality. *Andrologia*, 50 (3). <https://doi.org/10.1111/and.12888>
- Rao, A.R., Bane, A. & Gustafsson, B.K. (1980). Changes in the morphology of spermatozoa during their passage through the genital tract in dairy bulls with normal and impaired spermatogenesis. *Theriogenology*, 14 (1), 1–12. [https://doi.org/10.1016/0093-691X\(80\)90129-6](https://doi.org/10.1016/0093-691X(80)90129-6)
- Rijsselaere, T., Maes, D., Hoflack, G., Kruif, A.D. & Soom, A.V. (2007). Effect of body weight, age and breeding history on canine sperm quality parameters measured by the Hamilton-Thorne analyser. *Reproduction in Domestic Animals*, 42 (2), 143–148
- Root Kustritz, M.V. (2007). The value of canine semen evaluation for practitioners. *Theriogenology*, 68 (3), 329–337
- Root Kustritz, M.V., Olson, P.N., Johnston, S.D. & Root, T.K. (1998). The effects of stains and investigators on assessment of morphology of canine spermatozoa. *Journal of the American Animal Hospital Association*, 34 (4), 348–352. <https://doi.org/10.5326/15473317-34-4-348>
- Rota, A., Manuali, E., Caire, S. & Appino, S. (2008). Severe tail defects in the spermatozoa ejaculated by an English bulldog. *Journal of Veterinary Medical Science*, 70 (1), 123–125
- Saacke, R.G. (2008). Sperm morphology: Its relevance to compensable and uncompensable traits in semen. *Theriogenology*, 70 (3), 473–478
- Saacke, R.G., Dalton, J.C., Nadir, S., Nebel, R.L. & Bame, J.H. (2000). Relationship of seminal traits and insemination time to fertilization rate and embryo quality. *Animal Reproduction Science*, 60–61, 663–677
- Saacke, R.G., Dejarnette, J.M., Bame, J.H., Karabinus, D.S. & Whitman, S.S. (1998). Can spermatozoa with abnormal heads gain access to the ovum in artificially inseminated super- and single-ovulating cattle? *Theriogenology*, 50 (1), 117–128

- Santos, N.R., Krekeler, N., Schramme-Jossen, A. & Volkmann, D.H. (2006). The knobbed acrosome defect in four closely related dogs. *Theriogenology*, 66 (6), 1626–1628
- Seager, S.W.J. (1986). Artificial insemination in dogs. In: Burke, T.J. (ed.) *Small Animal Reproduction and Infertility: a Clinical Approach to Diagnosis and Treatment*. Philadelphia: Lea & Febiger, 207–217
- Sjaastad, Ø.V. (2010). *Physiology of Domestic Animals*. 2. ed. Oslo: Scandinavian Veterinary Press.
- Svenska Kennelklubben (2014). *Inavel – vad innebär det?*  
<https://www.skk.se/sv/uppfoeding/avel-och-uppfoeding/genetik-och-avel/inavel/>  
 [2020-12-08]
- Svenska Sennenhundklubbens avelsråd (2018). *Rasspecifik avelsstrategi RAS för Berner Sennen*.
- Tesi, M., Lazzarini, G., Magliaro, C., Abramo, F., Fanelli, D., Miragliotta, V. & Rota, A. (2020). Age-related changes of seminiferous tubule morphology, interstitial fibrosis and spermatogenesis in dogs. *Animal Reproduction Science*, 219, 106534.  
<https://doi.org/10.1016/j.anireprosci.2020.106534>
- Tesi, M., Sabatini, C., Vannozzi, I., Di Petta, G., Panzani, D., Camillo, F. & Rota, A. (2018). Variables affecting semen quality and its relation to fertility in the dog: A retrospective study. *Theriogenology*, 118, 34–39
- Thundathil, J., Meyer, R., Palasz, A.T., Barth, A.D. & Mapletoft, R.J. (2000). Effect of the knobbed acrosome defect in bovine sperm on IVF and embryo production. *Theriogenology*, 54 (6), 921–934
- Toyama, Y. & Itoh, Y. (1993). Ultrastructural features and pathogenesis of knobbed spermatozoa in a boar. *American Journal of Veterinary Research*, 54 (5), 743–749
- Varesi, S., Vernocchi, V., Faustini, M. & Luvoni, G.C. (2013). Morphological and acrosomal changes of canine spermatozoa during epididymal transit. *Acta Veterinaria Scandinavica*, 55 (1), 17
- Villaverde, A.I.S.B., Fioratti, E.G., Ramos, R.S., Neves, R.C.F., Cardoso, G.S., Landim-Alvarenga, F.C. & Lopes, M.D. (2013). High incidence of ‘Dag-like’ sperm defect in the domestic cat. *Journal of Feline Medicine and Surgery*, 15 (4), 317–322
- Waberski, D., Meding, S., Dirksen, G., Weitze, K.F., Leiding, C. & Hahn, R. (1994). Fertility of long-term-stored boar semen: Influence of extender (Androhep and Kiev), storage time and plasma droplets in the semen. *Animal Reproduction Science*, 36 (1), 145–151
- Wildt, D.E., Baas, E.J., Chakraborty, P.K., Wolfle, T.L. & Stewart, A.P. (1982). Influence of inbreeding on reproductive performance, ejaculate quality and testicular volume in the dog. *Theriogenology*, 17 (4), 445–452



- Williams, W.W. (1920). Technique of collecting semen for laboratory examination with a review of several diseased bulls. *Cornell Vet*, 10, 87–94
- Woodall, P.F. & Johnstone, I.P. (1988). Scrotal width as an index of testicular size in dogs and its relationship to body size. *Journal of Small Animal Practice*, 29 (8), 543–547
- World Health Organization (1999). *WHO Laboratory Manual for the Examination of Human Semen and Semen-Cervical Mucus Interaction*. 4th. ed Cambridge: Cambridge University Press. <https://lib.europe.eu/book/3008267/39eee0> [2021-01-02]
- Xu, H., Yuan, S.-Q., Zheng, Z.-H. & Yan, W. (2013). The cytoplasmic droplet may be indicative of sperm motility and normal spermiogenesis. *Asian Journal of Andrology*, 15 (6), 799–805

## Acknowledgements

This project received financial contribution from the Jan Skogsborgs stiftelse för utbildning rörande hundsjukdomar and Thure F och Karin Forsbergs fond, and means from SLU.

I would like to express my gratitude to all help received from all the kind and helpful dog owners, the spermatology laboratory of SLU, my two supervisors and my fellow veterinary students who were also a part of this project of male BMD. It was a pleasure to meet all the amazing dogs that participated in this project.

## Popular science summary

The Swedish mountain dog breed club has noted a trend of lower fertility within the breed Bernese mountain dog (BMD) with low whelping rates, small litter sizes, and a high number of stillborn puppies. To investigate this issue, the breed club initiated cooperation with the Swedish University of Agricultural Sciences (SLU) which in turn gave rise to his project. This project aimed to examine the semen quality of BMD to have an overall picture of the population and to investigate if their semen quality had any association with other parameters (e.g. age, weight, size of the testicles, the status of the prostates, previous medical treatment, breeding history).

We were able to collect semen samples from 65 BMD from all over the country, their testicles were also measured and examined. The owners were asked to provide information about their dogs' breeding history and previous medical issues and treatment. The semen samples were then analysed at the spermatology laboratory at SLU. The concentration of the sperm and the total number of sperm were counted, the structure and appearance of the sperm were evaluated under a microscope. Ten different sperm abnormalities (pathological heads, proximal droplets, detached heads, knobbed acrosomes, abnormal acrosomes, nuclear vacuoles, defective midpieces, single bent tails, coiled tails, double bent tails) were included in this study and the percentage of presence of each defect was counted for each semen sample obtained, as well as the percentage of normal-looking sperm.

The result showed that 76.9% of the dogs had a normal number of sperm and around half of the dogs had motility over 70% (meaning 70% of the sperm in their samples were moving forward when inspected under a microscope). The average percentage of normal sperm was 46.8%. However, the motility of the sperm was found to decrease with increasing age, and the percentages of two sperm defects also increased with age. Proximal cytoplasmic droplets, single bent tails and coiled tails were the most common sperm defects. The percentage of four of the sperm defects were found to be higher in dogs with abnormal consistency in at least one of their testicles and this implied that testicle palpation could be an easy and efficient way to spot dogs with potentially impaired sperm quality, but of course, a semen sample would be needed for evaluation. When comparing dogs that had been breeding, the motility of those that had offspring was higher than those without offspring.

Furthermore, the number of live normal sperm of 60% of the participants had fulfilled the minimum requirement for artificial insemination and therefore they are likely to be fertile.

The result of this study gave us a general picture of the semen quality of the Bernese mountain dog in Sweden. This information can be useful for future research of fertility study of this breed or other large dog breeds.